



EGYPTIAN ACADEMIC JOURNAL OF
BIOLOGICAL SCIENCES
ZOOLOGY


B



ISSN
2090-0759

WWW.EAJBS.EG.NET

Vol. 17 No. 1 (2025)



Protective Effect of Pumpkin Seed Oil Extract Against Hepatorenal Toxicity of Thioacetamide in Male Rats

Abubaker Al Malki¹; Moustafa Elnaggar^{1,2} and Talal Zari¹

¹Department of Biological Sciences, Faculty of Science, King Abdulaziz University, Jeddah, Saudi Arabia.

²Department of Zoology, Faculty of Sciences, Suez Canal University, Ismailia, Egypt.

*E-mail: Abubakeralmalki3@gmail.com

ARTICLE INFO

Article History

Received:31/12/2024

Accepted:4/2/2025

Available:8/2/2025

Keywords:

Thioacetamide,
Pumpkin seed oil,
Hepatorenal
Toxicity, Oxidative
Stress, Histology.

ABSTRACT

With the increasing prevalence of thioacetamide (TAA)-induced toxicity affecting human hepatorenal organs, exploring alternative therapeutic drugs with antioxidant properties is essential for safeguarding human health. This study examined the protective effect of Pumpkin seed oil (PSO, *Cucurbita pepo*) supplementation against TAA-induced toxicity on the liver, kidney, lipid profile, and oxidative stress in male rats. Forty adult male rats were divided into 4 groups as following: Group I served as (the control group); Group II (TAA-exposed group); Group III (TAA-exposed group treated with PSO); Group IV (PSO-treated). Biochemical analysis, including glucose (GLU), albumin (ALB), total protein (TP), total bilirubin (TBIL), cholesterol (CHOL), triglyceride (TG), high-density lipoprotein cholesterol (HDL-c), low density lipoprotein cholesterol (LDL-c), blood urea nitrogen (BUN), uric acid (UA), creatinine (CR) levels were measured. Enzyme activities, including alanine aminotransferase (ALT), aspartate aminotransferase (AST), alkaline phosphatase (ALP), lactate dehydrogenase (LDH) enzyme activities, alongside histopathological examination. Rats treated with TAA exhibited increased levels of GLU, ALT, AST, TBIL, TP, ALP, LDH, CHOL, TG, LDL-c, BUN, UA, and CR accompanied by decreased in ALB and HDL-c. Additionally, enzymatic and non-enzymatic antioxidants, including GSH and SOD showed a marked reduction in TAA-treated groups. PSO supplementation nearly normalized liver, kidney biomarkers, and lipid profile, with an elevation in antioxidant levels compared to the control group. Histopathological examinations revealed that TAA caused extensive liver injury, and renal impairment. PSO supplementation mitigated the alterations in the liver and kidney functions, lipids profiles, and antioxidant levels associated with TAA-induced hepatorenal toxicity.

INTRODUCTION

Thioacetamide (TAA), a potent hepatotoxic and nephrotoxic agent, is frequently used in experimental models to induce kidney and liver damage that mimics pathological conditions in human (Ezhilarasan, 2023). TAA-induced toxicity is primarily attributed to the generation of reactive oxygen species (ROS), lipid peroxidation, and inflammatory response that contribute to hepatocellular and renal damage (Ezhilarasan, 2023). Prolonged exposure to these toxicants may lead to gradual organ dysfunction, highlighting the importance of effective strategies to reduce the detrimental effects (Nazari *et al.*, 2023).

Natural products have garnered increasing attention for their potential to counteract the toxic effects of chemical agents due to their abundance of bioactive compounds with antioxidative and anti-inflammatory properties (Sairazi *et al.*, 2020). PSO, an extract from *Cucurbita pepo*, is a nutritionally rich source of polyunsaturated fatty acids, tocopherol, carotenoids, and phytosterols, all of which contribute to its therapeutic potential (Hu *et al.*,

2023). Studies have demonstrated that PSO exhibits significant antioxidative, anti-inflammatory, and cytoprotective activities, making it a promising candidate for mitigating organ damage caused by oxidative stress and inflammation (Paul *et al.*, 2020).

Despite its well-documented benefit, limited studies have explored the protective effects of PSO in TAA-induced hepatorenal toxicity. This study aims to investigate the efficacy of PSO in mitigating liver and kidney damage caused by TAA in male rats. By examining biochemical, histopathological, and oxidative stress markers, this work seeks to elucidate the potential mechanisms underlying PSO's protective effects and its relevance as a therapeutic agent for oxidative stress-related disorders.

MATERIALS AND METHODS

Experimental Design:

The rats were obtained from Experimental Animal Unit of King Fahd Medical Research Center, King Abdulaziz University, weighing 140-160 g were divided into four groups, with ten rats in each group. The following treatments with PSO were administered daily for six consecutive weeks as follows:

- **Group I:** Control group received NaCl (0.9 %, IP).
- **Group II:** TAA-treated group received TAA (250 mg/kg, IP).
- **Group III:** TAA-treated group received TAA (250 mg/kg, IP) + PSO (1.5 g/kg, IP).
- **Group IV:** PSO group, received PSO (1.5 g/kg, IP).

Chemicals:

Thioacetamide (TAA) was obtained from Sigma Chemical Co (Loba Chemicals, India). All chemicals used in the study were of the highest grade and purity, and Pumpkin Seed Oil (PSO) was purchased from Sigma Co (Sigma-Aldrich, USA).

Biochemical Assays:

Liver Function Tests: Serum alanine aminotransferase (ALT) and aspartate aminotransferase (AST) were measured using the Reitman and Frankel (1957) method. Albumin (ALB) was measured using Busher (1990) method. Total protein (TP) was assessed by the method of Peters Jr (1968). Lactate dehydrogenase (LDH) was measured using Stevens *et al.* (1983) method. Alkaline Phosphatase (ALP) was determined using McComb and Bowers Jr (1972) method. Total Bilirubin (TB) was determined according to Bonora *et al.* (1983) method.

Renal Function Tests: Blood urea nitrogen (BUN) was determined using Patton and Crouch (1977) method. Uric acid (UA) level was estimated using the Burtis and Ashwood (1994) method. Creatinine (CR) was measured by Moore and Sharer (2017) method.

Lipid Profile Tests: Triglycerides (TG) was determined using Fossati and Prencipe (1982) method. Total cholesterol (CHOL) concentration was determined using the Richmond (1973) method. High density lipoprotein-cholesterol (HDL-c) was determined by using the method of Warnick *et al.* (1983). Low-density lipoprotein-cholesterol (LDL-c) was measured by Friedewald *et al.*, (1972) equation.

Oxidative Stress Markers: Glutathione (GSH) level was estimated using Moron *et al.* (1979) method. Superoxide Dismutase (SOD) level was estimated using Misra and Fridovich (1972) method.

Glucose Metabolism: Blood glucose (GLU) was measured by Middleton and Griffiths (1957) method.

Histopathological Examination:

Liver and kidney tissues were fixed in 10% formalin, dehydrated through a graded series of alcohol concentrations, cleared with xylol, and embedded in paraffin wax. For histological examination, 5 μ m sections were cut and stained with Harris hematoxylin and eosin.

Statistical Analysis:

The results obtained were presented as mean \pm SD for comparison. The data were subjected to statistical analysis using Prism® software for Windows, version 9.50 (GraphPad, USA). The results were statistically analyzed using one-way ANOVA. A p-value $<$ 0.05 was considered statistically significant.

RESULTS

Figure 1 (A-G), illustrates the serum levels of ALT, AST, ALP and LDH among the experimental groups. In the TAA treated group, the serum level of ALT, AST, ALP were significantly elevated to 79.67 ± 22.5 , 99.72 ± 22.35 , 133.2 ± 14.5 and 435 ± 64.0 U/L, respectively, compared to the negative control group values 13.05 ± 1.47 , 15.37 ± 1.57 , 44.0 ± 4.33 and 146.3 ± 8.16 U/L, respectively. Treatment with PSO + TAA-group significantly decreased the serum levels of ALT, AST, ALP and LDH to 16.32 ± 3.43 , 20.72 ± 5.45 , 55.67 ± 5.92 and 170.3 ± 20.8 U/L, respectively compared to TAA group ($P < 0.0001$ for all). Treatment with PSO alone resulted in no significant differences in these parameters compared to the control group.

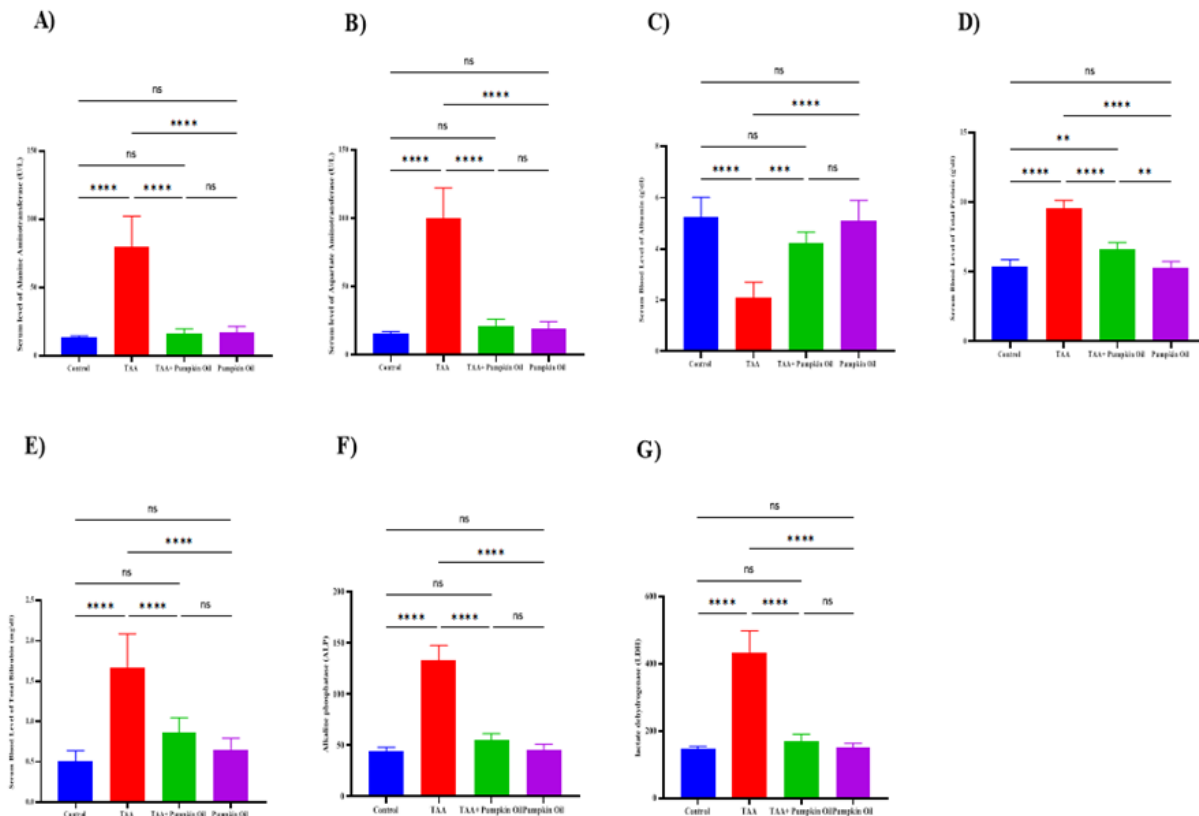


Fig. 1 (A-G). The serum measurement of Liver Functions, Alanine Aminotransferase (ALT), Aspartate Aminotransferase (AST), Albumin (Alb), Total Protein (T. P), Total Bilirubin (T. Bil), Alkaline Phosphatase (ALP) and Lactate dehydrogenase (LDH) in different studied groups being studied. Results are shown as mean \pm SD. Using One-way ANOVA (Tukey) test at $P < 0.05$. **: $P < 0.01$ and ***: $P < 0.001$ and ****: $P < 0.0001$.

Figure 2 (A-C), illustrates the level of BUN, UA, and CR across the different experimental groups. Oral administration of TAA induced abnormal kidney function in treated rats, as evidenced by a significant increase ($P < 0.05$) in serum BUN, UA, and CR compared to the control group. However, supplementation of PSO (1.5 ml/kg) with TAA significantly restored serum BUN, UA, and CR level to the normalcy level versus the control group. Furthermore, PSO treatment resulted in BUN, UA and CR levels approaching the normal range observed in the control group.

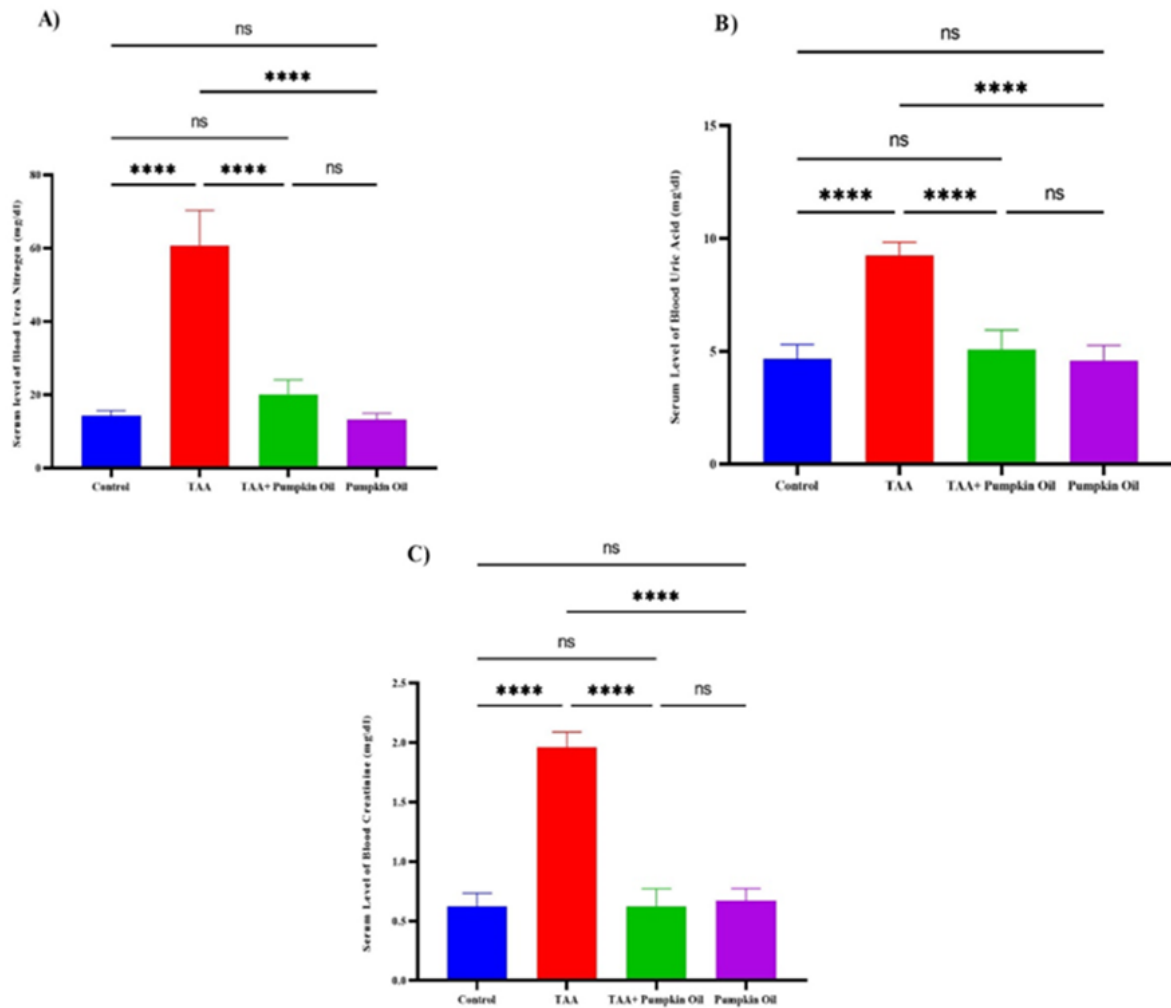


Fig. 2. Serum levels of Kidney function in different studied groups. **A)** represents serum Blood Urea Nitrogen (BUN, **B)** represents serum Uric Acid (UA), and **C)** represents serum creatinine. Data are presented as mean \pm standard deviation. Using One-way ANOVA (Tukey) test at $P < 0.05$. *: $P < 0.05$, **: $P < 0.01$ and ***: $P < 0.001$ and ****: $P < 0.0001$.

Figure 3 (A-D), illustrates the level of CHOL, TG, HDL-c, and LDL-c among different studied groups. Oral administration of TAA caused a significant alteration in the lipid profile of TAA-treated rats. Specifically, serum level of CHOL, TG, LDL-c were significantly elevated, while HDL-c levels were significantly reduced ($P < 0.05$) compared to control group. Supplementation of PSO with TAA significantly reduced serum CHOL, TG, LDL-c levels and increased HDL-c levels, restoring them approached control levels observed in the control group. Furthermore, PSO treatment showed the level of CHOL, TG, HDL-c, and LDL-c approached normal range observed in the control group.

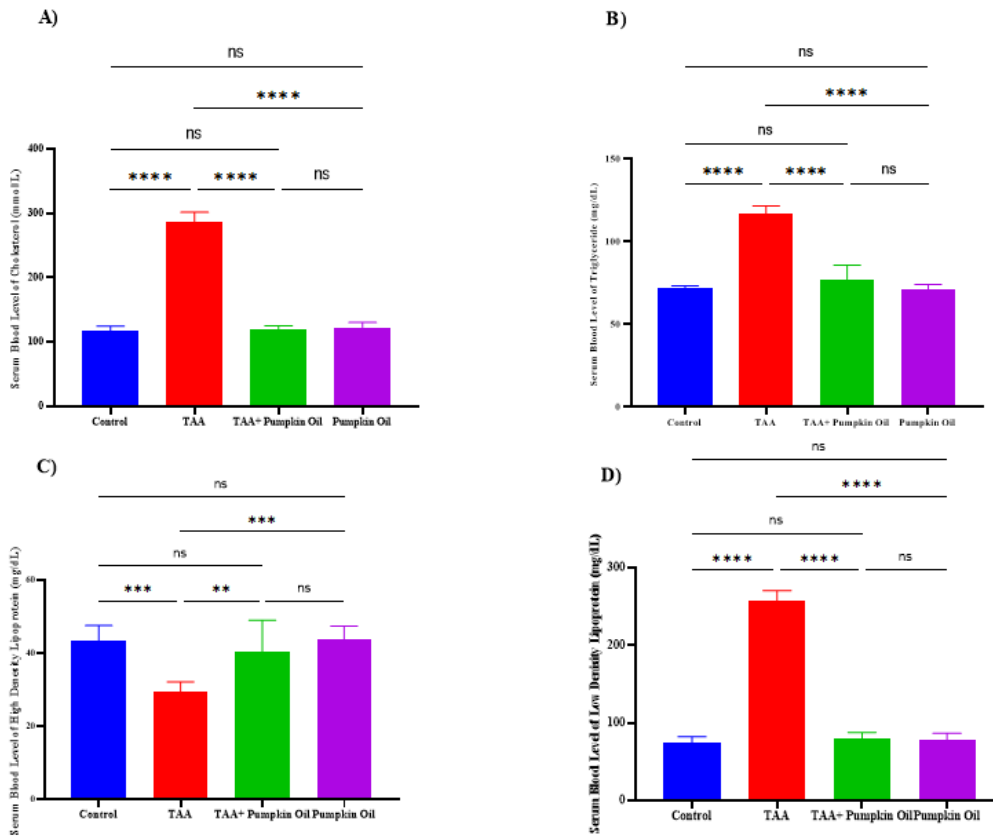


Fig. 3. Serum levels of Lipid profile in different studied groups. A) represents serum Cholesterol, B) represents serum Triglyceride, C) represents serum High-density lipoprotein, and D) represents Low-density lipoprotein among studied groups. Data are presented as mean +/- standard deviation. Using One-way ANOVA (Tukey) test at $P < 0.05$. *: $P < 0.05$, **: $P < 0.01$ and ***: $P < 0.001$ and ****: $P < 0.0001$.

Figure 4 (A-B), illustrates the level of GSH, and SOD among different studied groups. Oral administration of TAA caused a significant alteration in the antioxidant levels in TAA-treated rats. Specifically, serum level of GSH and SOD were significantly decreased ($P < 0.05$) compared to control group. Supplementation of PSO with TAA significantly restored the GSH and SOD levels closer to normal range observed in the control group. Furthermore, PSO treatment showed the level of GSH and SOD were closer to normal range observed in the control group.

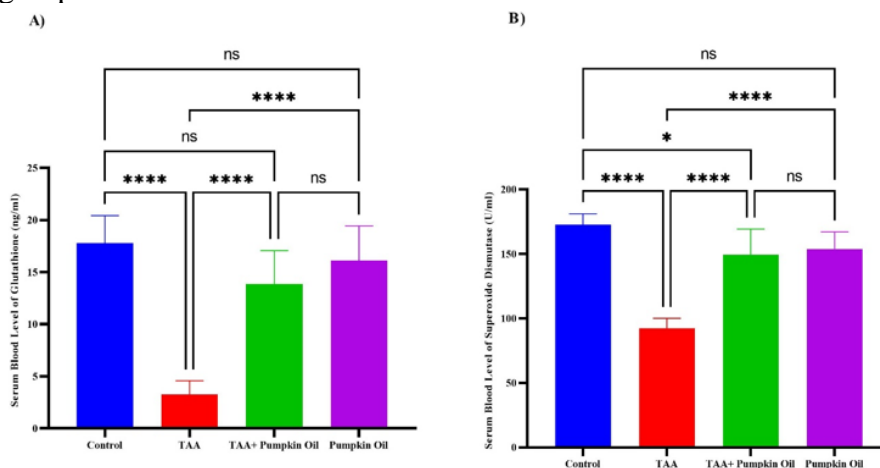


Fig. 4. Serum levels of Oxidative stress markers A) represent serum Glutathione (GSH), and B) represent Superoxide Dismutase (SOD) in different groups being studied. Data are presented as mean +/- standard deviation. Using One-way ANOVA (Tukey) test at $P < 0.05$. *: $P < 0.05$, **: $P < 0.01$ and ***: $P < 0.001$ and ****: $P < 0.0001$.

Histopathology:

Histopathological analysis of liver tissue demonstrates varying levels of structural changes across experimental groups. (Fig. 5A) Control group shows normal liver architecture with intact hepatocytes (HC), central vein (CV), and sinusoids (S). (Fig. 5B) TAA-treated group exhibits severe hepatic damage, including sinusoidal dilation, inflammatory infiltration (IF), and red blood cells (RBC) accumulation. (Fig. 5C) Combined TAA and PSO treatment alleviate the damage with partial restoration of sinusoidal and hepatocyte structure, along with reduced inflammatory changes. (Fig. 6D) PSO-treated group displays nearly normal liver histology compared to the control group, indicating the hepatoprotective effect of PSO.

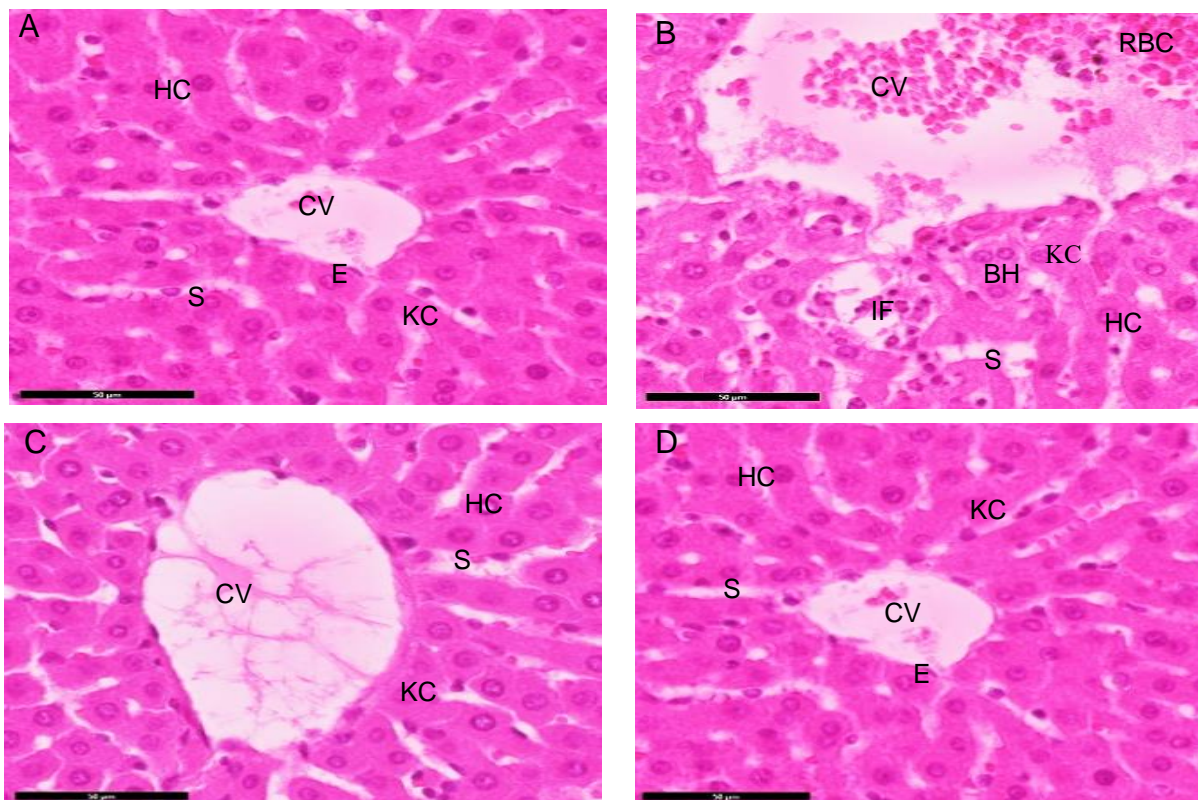


Fig. 5. Histopathological liver sections comparing different groups stained with Hematoxylin & Eosin, 100x magnification. (A) Normal architecture with central vein (CV), hepatocytes (HC), sinusoids (S), and Kupffer cells (KC). Inflammatory changes with dense infiltration (IF), bile hepatocytes (BH), and red blood cells (RBC) near the CV. (C) Mild disruption with slightly dilated sinusoid (S) and Kupffer cells (KC) activity. (D) Preserved hepatocytes (H) with minimal sinusoidal alteration. Scale bar = 50 μ m. The groups exhibit varying levels of inflammation and structural disruption, with (B) showing the most pronounced changes and (D) appearing approached to normal.

Figure 6, demonstrates that TAA treatment caused significant kidney damage, including glomerular congestion, tubular degeneration, and inflammatory infiltration (Fig. 6B). PSO administration to TAA-treated group mitigated these effects, showing partial restoration of glomerular and tubular structures and reduced inflammation (Fig. 6C). The PSO-treated group exhibited normal kidney histology compared to the control group, indicating its nephroprotective potential (Fig. 6D).

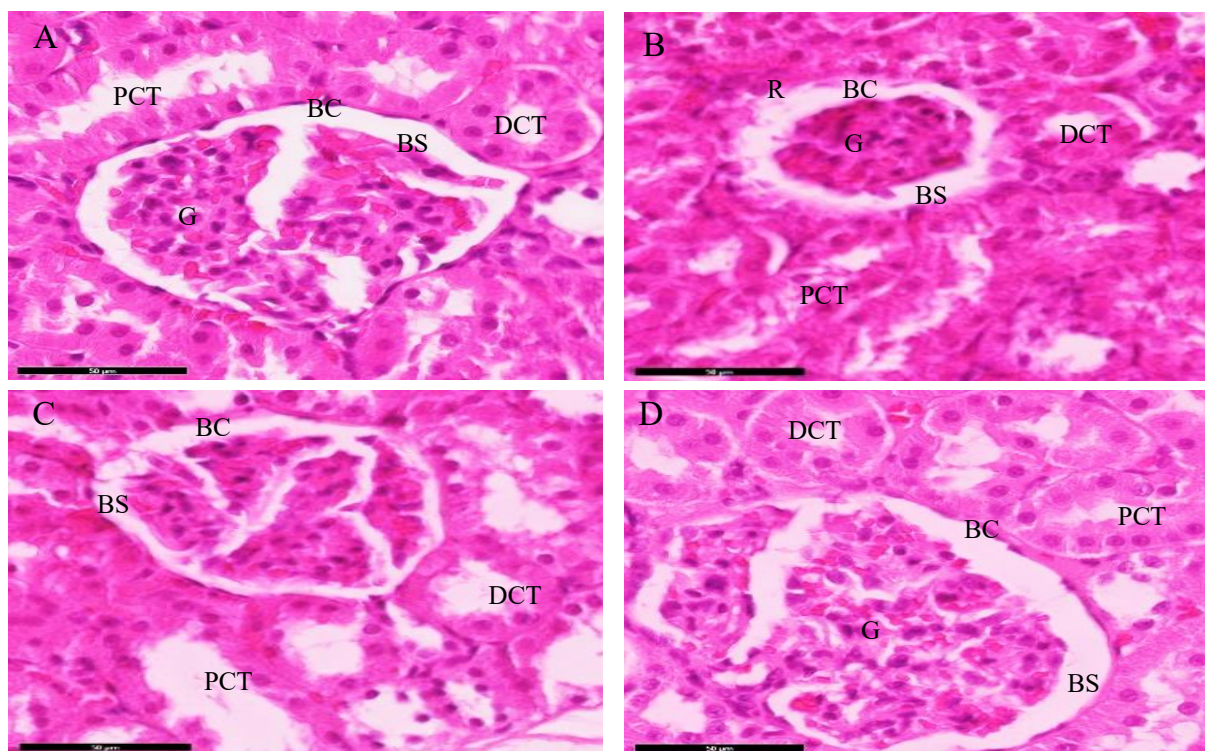


Fig. 6. Histopathological examination of kidney tissue of rats under various treatment conditions stained with Hematoxylin & Eosin, 100x magnification. (A) Control showed normal histopathological appearance. (B) TAA-treated rats showed infiltration and necrosis of the renal tubular. (C) Administration TAA-treated rats with Pumpkin oil showed an ameliorative effect in glomerular and renal tissue. (D) Administration of control with Pumpkin oil, showing no significant change versus the control group.

DISCUSSION

This study provides compelling evidence for the protective role of pumpkin seed oil (PSO) against thioacetamide (TAA)-induced hepatorenal toxicity in male rats. TAA, a Sulfur-containing compound, induces severe oxidative stress and organ damage by generating reactive oxygen species (ROS), promoting lipid peroxidation, and triggering inflammation. In this study, TAA exposure significantly disrupted liver and kidney functions, altered lipid profiles, and depleted antioxidant defenses. These changes are consistent with earlier studies reporting that TAA-induced elevations in liver enzymes (ALT, AST, ALP, and LDH), kidney dysfunction markers (BUN, U.A, CR), and dyslipidemia including increased level of CHOL, TG, and LDL-c and along with decreased HDL-c levels (El-Hameed *et al.*, 2024).

Biochemically, these alterations reflect the extensive cellular damage caused by TAA through oxidative, and inflammatory mechanisms. Histological analysis corroborated these results, revealing severe hepatic damage, such as sinusoidal dilation, fatty degeneration, and necrosis. Renal damage characterized by glomerular congestion, tubular degeneration, and inflammatory infiltration. The antioxidant findings further support this mechanism, showing significant depletion of endogenous antioxidants in TAA-treated rats. In contrast, PSO treatment ameliorated the biochemical and histological abnormalities restoring antioxidant defenses, reducing lipid peroxidation, and alleviating cellular damage.

PSO supplementation, however, significantly mitigated these adverse effects. Rats treated with PSO displayed notable improvements in liver and kidney function markers and lipid profiles. The restoration of antioxidant enzymes, including GSH, and SOD, underscores the antioxidant capacity of PSO in combating oxidative stress. These results align with the antioxidative, and anti-inflammatory properties attributed to PSO's bioactive compounds, such as phytosterols, essential fatty acids, and vitamin E (Gedi, 2022). Previous studies have

also reported the efficacy of PSO in ameliorating oxidative damage in aflatoxin and cisplatin-induced models (Liang *et al.*, 2021). The findings from this study expand on this body of evidence, demonstrating the effectiveness of PSO in reducing TAA-induced toxicity, a model known for severe hepatorenal damage.

The histological analyses in this study further validate the biochemical findings. TAA caused extensive liver damage, including sinusoidal dilation, fatty degeneration, and necrosis consistent with its hepatotoxic nature (Faisal & Al-Saidya, 2022). Similarly, renal damage in TAA-exposed rats was evidenced by glomerular and tubular injury, inflammatory infiltration, and cellular degeneration. PSO treatment significantly mitigated these histological changes, reducing liver and kidney damage and restoring tissue architecture to near-normal conditions. These protective effects are consistent with earlier studies showing PSO's ability to stabilize cellular membranes, inhibit MDA, and scavenge ROS (Areebambud *et al.*, 2023). The bioactive components of PSO likely contribute to its efficacy. Essential fatty acids in PSO, including linoleic and oleic acids, are known to enhance membrane integrity and modulate inflammation (Hu *et al.*, 2023). Phytosterol may also play a role by reducing cholesterol absorption and regulating lipid metabolism, thereby contributing to the observed improvements in lipid profile (Elsenousy *et al.*, 2019). Vitamin E and phenolic compounds in PSO act as potent antioxidants, neutralizing ROS and reducing oxidative damage to cellular components (Rohman & Irnawati, 2019). These mechanisms collectively support the multifaceted protective effect of PSO against oxidative damage and inflammation.

Moreover, the hypolipidemic effects of PSO observed in this study are of particular interest, as dyslipidemia is a hallmark of TAA-induced toxicity (Mirmiran *et al.*, 2010). The reduction in Chol, T.G, and LDL-c levels, alongside the restoration of HDL-c highlights the potential of PSO in managing lipid metabolism disorders. These effects could have broader implications for the use of PSO in conditions associated with oxidative stress and dyslipidemia, such as metabolic syndrome, diabetes, and cardiovascular diseases. However, while the findings of this study are promising, further research is needed to explore the molecular pathways underlying the PSO's protective effects. Investigating its influence on oxidative stress markers, inflammatory cytokines, and lipid metabolism at the genetic and proteomic levels could provide deeper insights into its mechanisms of action. Additionally, studies in chronic exposure models and human clinical trials are necessary to validate its effectiveness and safety in broader applications.

Conclusion

The protective effects of PSO against TAA-induced hepatorenal toxicity, as demonstrated in this study, emphasize its therapeutic potential as an antioxidant and anti-inflammatory agent. These findings contribute to the growing body of evidence supporting the health benefits of PSO but also underscore its potential as a complementary approach to managing liver and kidney disorders associated with oxidative stress and inflammation. Further exploration of PSO's clinical applications could pave the way for its inclusion in therapeutic regimens targeting chemical-induced toxicity and related conditions.

Declarations:

Ethical Approval: The experiments were processed using the animal ethical rules of King Abdulaziz University's Animal Care and Use Committee (ACUC). Furthermore, all tests adhered to the Arrive standards and the EU Directive 2010/63/EU regarding animal research.

Competing interests: The authors declare that there is no conflict of interest regarding the publication of this paper.

Author's Contributions: Abubaker Al Malki write the manuscript Moustafa Elnaggar and Talal Zari revised the manuscript.

Funding: This study didn't receive any funding support.

Availability of Data and Materials: The collection of data developed and/or assessed throughout the present work is available through the corresponding author upon reasonable request.

Acknowledgments: We would like to express our sincere gratitude to Muhamed A. El Nobey for his invaluable guidance and mentorship throughout this study. We also thank Mohammed Y. Alomar for providing the facilities required for this work.

REFERENCES

- Areebambud, C., Sareedenchai, V., Jariyapongskul, A., & Tadtong, S. (2023). Pumpkin seed oil protects SH-SY5Y cells against amyloid-beta 42-induced oxidative stress and neuronal cell death. *Science, Engineering and Health Studies*, 23050019-23050019
- Bonora, R., Malchiodi, A., & Panteghini, M. (1983). A single reagent method for determination of total and conjugated bilirubin with a centrifugal analyzer. *Clinica Chimica Acta*, 128(2-3), pp. 407-414.
- Burtis CA, Ashwood ER. Tietz textbook of clinical chemistry and molecular diagnostics. London, UK: WB Saunders, 1994.
- Busher, J. T. (1990). Serum albumin and globulin. *Clinical methods: The history, physical, and laboratory examinations*, 3, 497-499.
- El-Hameed, S. A., Ibrahim, I., Awadin, W. F., & El-Shaieb, A. (2024). Assessment of single and combined administration of ubiquinone and lactoferrin on histopathology, ultrastructure, oxidative stress, and WNT4 expression gene induced by thioacetamide on hepatorenal system of adult male rats. *Beni-Suef University Journal of Basic and Applied Sciences*, 13(1),41.
- Elsenousy, A., Farid, A. S., & Fararh, K. M. (2019). Effect of pumpkin seed oil on lipid metabolism in experimental hyperlipidemic rats. *Benha Veterinary Medical Journal*.
- Ezhilarasan, D. (2023). Molecular mechanisms in thioacetamide-induced acute and chronic liver injury models. *Environmental toxicology and pharmacology*, 99, 104093.
- Faisul, A. G., & Al-Saidya, A. M. (2022). Pathological Aspects of Rabbits Hepatotoxicity and Fibrosis Experimentally Induced by Thioacetamide and The Role of Silymarin as Anti fibrotic Effects. *Egyptian Journal of Veterinary Sciences*, 54(1), 23-30.
- Fossati, P., & Prencipe, L. (1982). Serum triglycerides are determined colorimetrically with an enzyme that produces hydrogen peroxide. *Clinical chemistry*, 28(10), 2077-2080.
- Friedewald, W. T., Levy, R. I., & Fredrickson, D. S. (1972). Estimation of the concentration of low-density lipoprotein cholesterol in plasma, without use of the preparative ultracentrifuge. *Clinical chemistry*, 18(6), 499-502.
- Gedi, M. A. (2022). Pumpkin seed oil components and biological activities. *Multiple Biological Activities of Unconventional Seed Oils*, (pp. 171-184)
- Hu, Z., Hu, C., Li, Y., Jiang, Q., Li, Q., & Fang, C. (2023). Pumpkin seed oil: A comprehensive review of extraction methods, nutritional constituents and health benefits. *Journal of the science of food and agriculture*, 104(2), 572-582.
- Liang, Z., Chen, Y., Wang, Z., Wu, X., Deng, C., Wang, C., Yang, W., Tian, Y., Zhang, S., Lu, C., & Yang, Y. (2021). Protective effects and mechanisms of psoralidin against adriamycin-induced cardiotoxicity. *Journal of Advanced Research*, 40, 249 - 261.
- McComb, R. B., & Bowers Jr, G. N. (1972). Study of optimum buffer conditions for measuring alkaline phosphatase activity in human serum. *Clinical chemistry*, 18(2), 97-104.
- Middleton, J., & Griffiths, W. (1957). Rapid colorimetric micro-method for estimating glucose in blood and CSF using glucose oxidase. *British medical journal*, 2(5060), 1525.
- Mirmiran, P., Fazeli, M. R., Asghari, G., Shafiee, A., & Azizi, F. (2010). Effect of pomegranate seed oil on hyperlipidaemic subjects: a double-blind placebo-controlled clinical trial. *British Journal of Nutrition*, 104, 402 - 406.
- Misra, H. P., & Fridovich, I. (1972). The role of superoxide anion in the autoxidation of epinephrine and a simple assay for superoxide dismutase. *Journal of Biological chemistry*, 247(10), 3170-3175.
- Moore, J. F., & Sharer, J. D. (2017). Methods for quantitative creatinine determination. *Current protocols in human genetics*, 93(1), A. 30. 1-A. 30. 7.
- Moron, M. S., Depierre, J. W., & Mannervik, B. (1979). Levels of glutathione reductase, and glutathione S-transferase activities in rat lung and liver. *Biochimica et biophysica acta (BBA)-general subjects*, 582(1), 67-78.
- Nazari, M., Heidari, R., Hami, Z., Shiri, M., Nassireslami, E., & Chamanara, M. (2023). Some relevant mitigating agents of chronic aflatoxin exposure: a treatise. *Drug and chemical toxicology*, 47(5), 807-816.

- Patton, G. and Crouch, S. (1977). Colorimetric Method for the Determination of Serum Urea. *Analytical chemistry*, 49(3), 464-469.
- Paul, M., Sohag, M. S. U., Khan, A., Barman, R. K., Wahed, M. I. I., & Khan, M. R. I. (2020). Pumpkin (*Cucurbita maxima*) seeds protect against formaldehyde-induced major organ damages. *Heliyon*, 6(8).
- Peters Jr, T. (1968). Proposals for standardization of total protein assays. *Clinical chemistry*, 14(12), 1147-1159.
- Reitman, S., & Frankel, S. (1957). A colorimetric method for the determination of serum glutamic oxalacetic and glutamic pyruvic transaminases. *American journal of clinical pathology*, 28(1), 56-63.
- Richmond, W. (1973). Preparation and properties of a cholesterol oxidase from *Nocardia* sp. and its application to the enzymatic assay of total cholesterol in serum. *Clinical chemistry*, 19(12), 1350-1356.
- Rohman, A., & Irnawati. (2019). Pumpkin (*Cucurbita maxima*) seed oil: chemical composition, antioxidant activities and its authentication analysis. *Food Research*.
- Sairazi, N. S. A. M., Sirajudeen, K. N. S., & Sirajudeen, K. N. S. (2020). Natural Products and Their Bioactive Compounds: Neuroprotective Potentials against Neurodegenerative Diseases. *Evidence-based Complementary and Alternative Medicine: eCAM*, 2020.
- Stevens, J., Tsang, W., & Newall, R. (1983). Measurement of the enzymes lactate dehydrogenase and creatine kinase using reflectance spectroscopy and reagent strips. *Journal of clinical pathology*, 36(12), 1371-1376.
- Warnick, G. R., Benderson, V., & Albers, N. (1983). Estimation of HDL-cholesterol selected methods. *Clinical chemistry*, 1, 91-99.