



EGYPTIAN ACADEMIC JOURNAL OF
BIOLOGICAL SCIENCES
ZOOLOGY


B



ISSN
2090-0759

WWW.EAJBS.EG.NET

Vol. 12 No. 1 (2020)



Protective Effect of Graviola (*Annona muricata*) Leaves Extract Against Cadmium-Induced Testicular Toxicity In Male Albino Rats

Dalia D. Abd El-Monem and Shereen H.B. Elwakeel*

Zoology Department, Faculty of Women for Arts, Science and Education, Ain Shams University, Asmaa Fahmy Street, Heliopolis, Cairo, Egypt.

E.Mail: sherien.elwakeel@women.asu.edu.eg - dalia.demerdash@women.asu.edu.eg

ARTICLE INFO

Article History

Received:15/5/2020

Accepted:30/6/2020

Keywords:

Cadmium chloride,
Graviola,
sperm-parameter,
DNA-damage,
apoptosis

ABSTRACT

Graviola (*Annona muricata*), an edible plant belonging to the Annonaceae family, has a long history in traditional medicine due to its wide range of therapeutic effects on many ailments. This study was planned to assess the protective potentials of Graviola leaves extract (GLE) on cadmium-induced testicular damage in male albino rats. The study was conducted on 32 male adult Wistar rats randomly divided into four groups (n=8/each). A (control group); B (GLE, 100 mg/kg); C (cadmium chloride (CdCl₂), 5 mg/kg) and D (GLE, 100 mg/kg + CdCl₂ 5 mg/kg). All administrations were performed by daily gavage for 8 weeks. Blood, testes, and epididymis were harvested for biochemical and histological investigations. In addition to sperm analysis, sperm DNA comet assay, and apoptotic indices. Results revealed that GLE significantly reversed (p<0.05) testicular oxidative stress induced by CdCl₂, maintained male sex hormones levels, and restored testis architecture via increasing the testicular antioxidant status. GLE co-treatment significantly increased (p<0.05) sperm count, motility, viability, and DNA integrity along with significantly reducing sperm DNA damage and sperm head abnormality in comparison with CdCl₂ group. Additionally, GLE protected germ cells from Cd-induced apoptosis. In conclusion, results of the present study confirmed that GLE has potent antioxidant potentials and cytoprotective capacity against the deleterious effects of CdCl₂ on testicular tissue by reducing cellular oxidative stress prompted by the generation of the reactive oxygen species.

INTRODUCTION

Cadmium (Cd) is a toxic heavy metal found in the earth's crust combined with other elements, such as oxygen, chlorine, carbon, nitrogen, hydrogen, and sulfur. The main ways for Cd exposure are through industrial emissions, cigarette smoke, agricultural fertilizers, and ingestion of Cd found in certain food and water (Richter *et al.*, 2017; Satarug *et al.*, 2010). Workers can expose to Cd contamination during the manufacturing of paints, batteries, or during plating, soldering, and welding (Wang *et al.*, 2011). Cd toxicity is due to acute and chronic exposure which can occur from oral exposure to Cd, as well as respiratory exposure (Lech and Sadlik, 2017). The risk of Cd exposure is due to its prolonged half-life (about 20–30 years in humans), its low body elimination rate and its accumulation in the body organs (Bu *et al.*, 2011), causing extensive damage to almost all biological tissues, especially liver and kidney (Alese *et al.*, 2018). Moreover, several studies displayed the sensitivity of

testicular tissues to Cd toxicity through altering the testicular structure and function (Marettova *et al.*, 2015), causing infertility through decreasing sperm count, motility, viability, and testosterone level (Monsefi *et al.*, 2010). Cd can influence several critical cellular processes, such as cell division, proliferation, differentiation, and apoptosis (Bertin and Averbek, 2006). Cd causes oxidative stress by producing reactive oxygen species (ROS), such as superoxide ion ($O_2^{\bullet-}$), hydrogen peroxide (H_2O_2), and hydroxyl radical ($\bullet OH$) (Ikediobi *et al.*, 2004). Naturally, immature spermatozoa and leukocytes produce low amounts of ROS which kept in equilibrium with the antioxidant activities in the reproductive tract (Henkel, 2011). The low levels of ROS are essential for sperm optimal function, promote sperm capacitation, regulate sperm maturation, hyperactivation, acrosomal reaction, and enhance cellular signaling pathways as well as fusion with the female gamete (Du Plessis *et al.*, 2015). However, when excess amounts of ROS are generated or when antioxidant activity fails, this equilibrium state is disrupted, leading to oxidative stress (Valko *et al.*, 2005). Where, ROS attack the phospholipids in the testosterone-secreting cell membrane, lessen the hormonal effects and harm many cellular components, such as enzymes, protein, and DNA (Patra *et al.*, 2011), thus rising infertility incidence. 25%–80% of infertile men have significant levels of ROS in their semen (Agarwal *et al.*, 2006). Such ROS must be neutralized by antioxidants before entering the cells.

Antioxidants act as powerful scavengers of free radicals and prevent the occurrence of many diseases. Recently, numerous studies have reported the protective effects of flavonoids products on the treatment of toxicity (Lim *et al.*, 2019). Graviola (*Annona muricata*) is a tropical and subtropical evergreen fruit tree belongs to the Annonaceae family which includes around 130 genera and 2,300 species (Mishra *et al.*, 2013). Graviola is famous as soursop, guanabana, custard apple, and sirsak. The extract of the different parts of Graviola plant is rich in numerous phytoconstituents, including flavonoids (luteolin, homoorientin, tangeretin, quercetin, rutin, and daidzein), alkaloids, glycoside, epicatechin gallate, emodin, coumaric acid, megastigmanes, phenolics, cyclopeptides, and essential oils (George *et al.*, 2015; Yang *et al.*, 2015). Therefore, all parts of Graviola tree, such as bark, leaves, pericarp, fruits, seeds, and roots are used around the world in the traditional medicine against an array of human ailments and diseases, such as headaches, diabetes, skin diseases asthma, hypertension, cough, peptic ulcers, liver problems, mental disorders, and cancers (Coria-Téllez *et al.*, 2018; Quílez *et al.*, 2018). Additionally, the leaves of Graviola are used in wound healing (Moghadamtousi *et al.*, 2015) and as an anti-inflammatory, antidiysenteric, and antispasmodic (de Sousa *et al.*, 2010). Moreover, Graviola is a rich source of annonaceous acetogenin (ACGs) compounds that display antitumor, pesticidal, antimalarial, anthelmintic, antiviral, antimicrobial, and antifungal effects (Pomper *et al.*, 2009). Several recent studies on a variety of cancer cell lines have related Graviola derived compounds such as ACGs to a series of anti-cancer effects including cytotoxicity, cell cycle arrest, antiproliferation, and induction of apoptosis or necrosis, (Qazi *et al.*, 2018), while having little to no effect on the normal cell viability. Thus, due to the prevalent of Cd in the environment and its deleterious effects on the reproductive system even under exposure to very small doses and the benefits of Graviola leaves as a safe and cheap nutritional compound that contains phytochemicals and have promising antioxidant potentials. The present study was designated to help in finding a protective therapeutic approach to prevent the destructive effect of oxidative stress induced by Cd in the male reproductive system.

MATERIALS AND METHODS

Chemicals:

Graviola (*A. muricata*) leaves powdered capsules (natural product drug) was obtained from Cures Pharma (USA). Each capsule contains 750 mg of concentrated Graviola leaves. The content of each capsule was dissolved in distilled water just before use. Cadmium chloride (CdCl_2) was obtained from Sigma-Aldrich Co., (St Louis, MO). All other chemicals and solvent used during the experiment were fit the highest purity grade value.

Animals and Experimental Design:

Thirty-two sexually mature male Wistar albino rats weighing approximately 190 ± 20 g (10–13 weeks old) were used during the study. The animals were purchased from the animal house of The National Research Center, El Buhouth St., Dokki, Cairo, Egypt. Rats were randomly distributed into four groups, eight animals each and kept in stainless steel cages under standard laboratory conditions at good ventilation and 12-hour light-dark cycle with free access to standard commercial laboratory food and tap water. Rats were allowed to adapt to the laboratory conditions for 2 weeks before the beginning of the experiment. The experimental design was categorized as the following:

Group A: served as negative control and was given distilled water.

Group B: rats were received 100 mg/kg b.w. of Graviola leaves extract (GLE) dissolved in distilled water the dose was chosen according to the previous work of Adewole and Ojewole (2008).

Group C: (Treated group) animals were received 5 mg/kg b.w. of CdCl_2 dissolved in distilled water according to Nna *et al.* (2017).

Group D: (Co-treated group) rats were received 100 mg/kg b.w. GLE two hours before receiving 5 mg/kg b.w. of CdCl_2 .

All administrations were performed by daily gavage for 8 weeks. 24-hours after the last treatment, animals were slightly anaesthetized with ether and blood were collected slowly from the heart in a clean dry test tube, left for at least 30 minutes to coagulate and centrifuged to obtain serum. After blood collection, animals were euthanized by cervical dislocation and both testes and cauda epididymis were dissected out for further investigation. All animal procedures were accomplished in accordance with the guidelines for the care and use of experimental animals established by the Committee for the Purpose of Control and Supervision of Experiments on Animals and the National Institutes of Health protocol approved by Ain Shams University.

Biochemical Assays:

Antioxidant Enzymes and Lipid Peroxidation Marker Assays:

The left testis from each animal was homogenized in cold (10 mM) phosphate-buffered saline (PBS) with optimal pH 7.4, centrifuged, and part of the supernatant was used for the following:

Superoxide Dismutase (SOD) Activity:

Superoxide dismutase activity was evaluated in testicular tissue as stated by Sun *et al.* (1988), which utilizes the xanthine–xanthine oxidase system to produce superoxide flux, and employing the inhibition of nitroblue tetrazolium reduction as an indication of superoxide generation. The resulted product was spectrophotometrically at 560 nm and was expressed as u/g.

Catalase (CAT) Activity:

The measurement of testicular CAT enzyme activity was spectrophotometrically done by measuring the decomposition of H_2O_2 at 410 nm as stated by Aebi (1983).

Glutathione (GSH) Content:

Testis GSH content was estimated using the colorimetric technique as described by Ellman (1959) which based on the development of yellow colour when 5,5'-dithiobis (2-nitrobenzoic acid) is added to compound contains sulfhydryl groups. The absorbance was measured at 412 nm and the concentration of GSH was calculated using the standard curve.

Malondialdehyde (MDA) Level:

The concentration of testicular MDA was spectrophotometrically evaluated as a thiobarbituric acid-reactive substance (TBARS) as described by Pedeson *et al.* (1990) based on the maximum absorption of the malondialdehyde complex and other TBARS.

Hormones Determination:

Testosterone levels in testicular tissue, serum Luteinizing hormone (LH), and Follicle-stimulating hormone (FSH) were measured using the enzyme-linked immunosorbent assay (ELISA) method. The DRG ELISA testosterone kit (My BioSource.com, USA, Catalog Number: MBS282195), Rat luteinizing hormone ELISA Kit (CUSABIO, Catalog Number. CSB-E12654r), and Rat FSH ELISA Kit (CUSABIO, Catalog Number. CSB-E06869r) were used according to the kit manufacturer's instructions.

Histopathological Investigation:

Right testes were collected, rapidly rinsed in an isotonic solution, and fixed in a 10% formalin solution for 72 hours. Samples were then dehydrated with ethanol, cleared in xylene, immersed in paraffin wax, cut into 5 µm thick sections, and stained with Hematoxylin and Eosin (H&E).

Epididymal Sperm Parameters:**Sperm Suspension:**

The epididymis was dissected out, trimmed free of fat, and placed in a Petri dish containing 2 ml of Hams F-10 media (Bio Sense, El Haram, Giza, Egypt). Several deep cuts were made in epididymal tissue and incubated at 37°C in an atmosphere of 5% CO₂ for 5 minutes to allow sperms to swim out into the medium. All sperm parameters were performed as described by Rezvanfar *et al.* (2008) as follows:

Sperm Count:

Five microliters aliquot of sperm suspension was diluted with 95 µl of formaldehyde fixative (10% formalin in PBS). Then, 10 µl of the diluted mixture was placed on each of the counting chambers of the improved hemocytometer slide and was permitted to stand for 2 minutes. Sperm heads were manually counted using a 400× light microscope. The data were expressed by the number of sperms in millions/ml.

Sperm Viability:

The dye exclusion method was used to assess sperm viability. Briefly, equal volumes of sperm suspension and Eosin-nigrosin stain were mixed well, and instantly one drop of the mixture was smeared and observed under 400× magnification using a light microscope. Dead sperms seemed pink and live sperms were colourless. Two hundred sperm/sample were counted to calculate the percentage of live sperms.

Sperm Motility:

Ten microliters of sperm suspension were placed on a pre-warmed microscopic slide, covered with a coverslip and examined within 2–4 minutes of their isolation from the epididymis at 400× magnification using the light microscope. Two hundred sperms per rat were observed at five different microscopic fields to compute the percentage of motile sperm of the total sperm counted.

Sperm Morphology Assay:

One drop of sperm suspension was smeared on each microscopic slide, fixed with methanol, and stained with Hematoxylin and Eosin. 1,000 spermatozoa/each animal were scored under 1,000 \times magnification using the light microscope. Data were expressed as the percentage of normal sperms.

Sperm DNA Integrity Analysis:

The integrity of sperm DNA was assessed using acridine orange (AO) stain as detailed in the protocol described by Tejada *et al.* (1984). Briefly, sperms were smeared on microscopic slides and fixed for 14-hours in 3 methanol: 1acetic acid at 4°C, stained with AO (0.19% in phosphate citrate buffer, pH = 2.5) for 10 minutes, washed for 5 minutes, air-dried and inspected under 200 \times and 400 \times magnification using Zeiss Axiostar plus fluorescence microscope. Stained sperms were categorized as green-headed sperms (double-stranded DNA) normal, yellow-headed sperms (single-stranded DNA) abnormal. Two hundred sperm/slide were analyzed to calculate the percentage of double-stranded DNA.

Comet Assay (single-cell gel electrophoresis):

DNA damages in sperm cells were assessed using an alkaline comet assay as proposed by Simon and Carrell (2013). Sperm concentrations were adjusted to 6×10^6 spermatozoa/ml and 10 μ l of each sample was gently mixed with 90 μ l of low melting point agarose (0.7% in PBS). The mixtures were quickly placed on a microscope slides with frosted ends and pre-coated with 110 μ l of normal melting point agarose (1% in PBS), covered with a cover glass and left to solidify for 10 minutes on a cold plate at 4°C. After solidification, the cover-slips were cautiously removed and the slides were immersed in cooled lysis buffer [2.5 M NaCl, 10 mM Tris, (pH 10), 100 mM EDTA] with freshly added 10% dimethyl sulfoxide (DMSO) and 1% Triton X-100 for 12-hours at 4°C. 100 μ g/ml proteinase K was also added to the lysis buffer. After lysis, slides were drained off any remaining liquid, placed in the electrophoresis chamber, and incubated in cooled electrophoresis alkaline buffer (pH > 13) (300 mM NaOH, 1 mM Na₂EDTA) for 20 minutes at 4°C to allow DNA unwinding, then electrophoresed at 300 mA and 25 V for 30 minutes. After electrophoresis, the gel was neutralized by rinsing the slides with neutralizing buffer [0.4 M Tris (pH 7.5)] three times for 5 minutes each. Finally, slides were stained with 50 μ l of ethidium bromide (2 mg/ml), covered with cover glass, and examined at 400 \times magnifications using Zeiss Axiostar plus fluorescence microscope. A total of 100 cells from duplicated slides per sample were photographed and analyzed with TriTekCometScore freeware v1.5. system.

Quantitative RT-PCR for Caspase-3, Bax and Bcl-2 genes in Testicular Tissues:

Total RNAs were isolated from testicular tissue homogenate using the RNA Purification Kit (Qiagen, Valencia, CA) according to the manufacturer's instruction. The RNA concentration and purity were evaluated by determining the 260/280 ratio. First-strand cDNA was synthesized in a PCR Thermal Cycler using the SuperScript cDNA synthesis Kit (Thermo Fisher, Scientific) according to the manufacturer's instruction. The real-time PCR analysis was performed in an ABI prism 7500 sequence detector system (Applied Biosystems step one plus, Foster City, CA) using SYBR Green Master Mix (Qiagen, Valencia, CA). Primer sequences used for quantification were listed in Table 1.

The PCR conditions were initial denaturation at 95°C for 10 minutes, followed by 40 cycles of DNA amplification as follows: denaturation at 95°C for 15 seconds, annealing at 60°C for 15 seconds, extension at 72°C for 45 seconds and a final extension at 95°C for 15 seconds and 60°C for 1 minute. The cycle threshold (Ct) values were calculated for target genes and the housekeeping gene. Relative gene expression was determined using the $2^{-\Delta\Delta Ct}$ method (Livak and Schmittgen, 2001).

Table 1. The sequence of the primers used for real-time PCR

Caspase-3	
Forward primer	5'- ACTCTTGTGGGCAAACCCAA -3'
Reverse primer	5'- CTCTCCATGAGCAGTAGCCG -3'
BAX (Bcl-2 -associated X protein)	
Forward primer	5'- CCCTGTGCACTAAAGTGCCC -3'
Reverse primer	5'- TTCTTCACGATGGTGAGCG -3'
Bcl-2(B-cell lymphoma protein 2)	
Forward primer	5'- CTACGAGTGGGATGCTGGAG -3'
Reverse primer	5'- GTCAGATGGACACATGGTG -3'
Beta-actin (housekeeping gene)	
Forward primer	5'- TCT GGC ACC ACA CCT TCT ACA ATG -3'
Reverse primer	5'- AGC ACA GCC TGG ATA GCA ACG -3'

Statistical Analysis:

Data obtained were assessed for normal distribution then statistically analyzed using SPSS Statistics 20 (IBM Inc., USA). The comparison of data among groups was done using the One-way analysis of variance followed by Tukey's multiple comparison test. Histograms were carried out using Graph Pad Prism 8 (LaJolla, CA). The p value ≤ 0.05 was considered as statistically significant. Data were expressed as mean \pm SEM.

RESULTS AND DISCUSSION

Cadmium is an environmental and industrial pollutant, capable of inducing severe damage to various organs and tissues, including the testis. In the present study, results revealed non-significant differences ($p>0.05$) in the animals' body weight (Fig. 1A) and the ratio of testes to animals' body weight (Fig. 1B) between all experimental treated groups that results are consistent with Bu *et al.* (2011). Nevertheless, certain studies have reported a significant decrease in both body and testes weight after Cd exposure (Liu *et al.*, 2016; Nna *et al.*, 2017). Such different results may be attributable to the route of Cd administration, the duration of treatment, and the administered doses. Additionally, results showed that Cd increased testicular oxidative stress and lipid peroxidation through significantly decreasing ($p<0.05$) GSH content, SOD, and CAT activities along with increasing MDA levels in the testes tissues homogenates of the treated group compared with the control group (Table 2), these results concur with previous results of Liu *et al.* (2016). In addition, histological examination revealed the destructive impact of Cd on testicular tissue. Cd-induced marked degenerative changes, vacuolation of germinal epithelium, and pyknosis [Fig. 2C (arrow)] accompanied by interstitial oedema [Fig. 2C (star)] compared with both negative control and GLE group which showed normal testicular architecture of seminiferous tubules with apparent intact well organized germinal epithelium in different stages of development and maturation as well as intact interstitial tissue (Fig 2 A and B). The deleterious effects of Cd on testicular tissue are owed to the production of ROS, peroxidation of the plasma membrane, and thus the devastation of tissue cells. Cd reaches testicular cells through the blood-testis barrier distribution and influences Sertoli and spermatogenic cell physiology (Siu *et al.*, 2009). It shows its toxic effects through binding to proteins sulphhydryl groups and depleting of glutathione (Jomova and Valko, 2011), leading to the increased generation of ROS that influences the performance of the antioxidant enzymes responsible for the biological defence against oxidative stress. Also, Cd causes an imbalance of body microminerals as a consequence it alters the expression of SOD responsible for regulating

ROS generation (Kurutas, 2016). SOD inactivation may also arise due to the substitution of Mn or Zn by Cd at the enzyme functional site (Casalino *et al.*, 2002), resulting in the alteration of the enzyme functional groups and reduction in its activity. As a consequence, cellular lipid peroxidation increases (Yari *et al.*, 2016) causing sperm dysfunction. As well, results displayed that CdCl₂ has affected steroidogenesis and spermatogenesis via inducing a significant decrease ($p<0.05$) in the means of testicular testosterone level along with significant increase ($p<0.05$) in the means of LH and FSH levels (Table 3). Additionally, CdCl₂ displayed significant decrease ($p<0.05$) in the means of sperm motility, sperm viability (Fig. 3A) and sperm count accompanied by significant increase ($p<0.05$) in the mean percentage of sperm abnormalities (Table 4 and Fig. 3B) compared with the control group, these results in accordance with the previous results of Saha *et al.* (2019). Cd testicular impairment shown in the current study may result from the excess generation of ROS and the reduction of many minerals essential for the occurrence and maintenance of spermatogenesis (Cupertino *et al.*, 2017; Mouro *et al.*, 2019). Among the minerals reduced due to Cd exposure is Zn, which is essential for the production of testosterone (Baltaci *et al.*, 2019). Cd can also disturb the hypothalamic-pituitary-testicular axis (de Angelis *et al.*, 2017) and suppress Leydig cell testosterone synthesis and secretion (Liu *et al.*, 2013) that clarify the alteration of sperm parameters and the hormonal levels found in the current study. Another cause of sperm dysfunction is DNA damage, and apoptosis (Agarwal and Saleh, 2002). In the current study, AO staining showed that CdCl₂ had an obvious effect on the DNA integrity of the epididymal sperms (Table 4 and Fig. 3C), these results in harmony with Aitken (1999) who stated that oxidative stress attacks both the fluidity of sperm plasma membrane and the integrity of DNA in its nucleus. Also, CdCl₂ increased spermatozoal DNA damage by the significantly increasing ($p<0.01$) both tail moment and Olive tail moment values versus the control group (Fig. 4). Such findings are in accordance with Nair *et al.*, (2013) who suggested that Cd exposure decreases the activity of antioxidant enzymes, increases cellular lipid peroxidation and DNA oxidation in rat testis. Moreover, our result displayed that Cd triggered an apoptotic cascade in testicular tissues via inducing a significant increase ($p<0.001$) in the expression level of pro-apoptotic markers caspase-3 and Bax genes and a significant decrease ($p<0.001$) in the expression level of anti-apoptotic Bcl-2 gene compared to the control group (Fig. 5). Such obtained data are similar to those of Nna *et al.* (2017). It has been suggested that the induction of apoptosis in testicular tissue is connected to oxidative stress (Turner and Lysiak, 2008). The oxidative stress impairs the mitochondrial membrane permeability and alters the associations between pro-apoptotic and anti-apoptotic members of the Bcl-2 family, causing the release of cytochrome C from the mitochondria where it activates caspase cascade (Hengartner, 2000), and finally results in the cell's DNA fragmentation.

On the other hand, the findings of the current study revealed that the GLE pre-treatment possessed an antioxidant effect through significantly increasing ($p<0.05$) SOD, CAT enzyme, and GSH content accompanied by significantly decreasing MDA level versus CdCl₂ group (Table 2). The antioxidant effect of Graviola that has emerged in this study may be attributed to the presence of phytochemicals in its constituents, including flavonoids and alkaloids (George *et al.*, 2015) which helps in chelating metal ions and scavenging of O₂•-, H₂O₂ and •OH radicals (Adefegha *et al.*, 2015) Also, Graviola comprises non-enzymatic antioxidants, such as Vitamin E, Vitamin C, carotenoids, and enzymatic antioxidants including CAT, glutathione reductase (GR), and SOD in its constituents (Muthu and Durairaj, 2015; Vijayameena *et al.*, 2013). Graviola's antioxidants minimized cell stress, suppressed cell peroxidation, and enhanced the co-treated group's antioxidant status, similar results are documented (Adewole and Ojewole, 2008; Olakunle *et al.*, 2014). GLE pre-treatment enhanced tissue architecture which appeared more organized almost intact germinal epithelium with milder records of degenerative changes (Fig 2D); these results are similar to

the finding of El-Sawi *et al.* (2020). It can be argued that oxidants' effects of CdCl₂ are diminished by Graviola's antioxidants. In addition, the current study displayed that the administration of GLE alone did not significantly ($p>0.05$) affect male sex hormonal levels, sperm parameters, and testicular structure which indicate the safety of GLE and agree with the conclusion of Awodele *et al.* (2013). GLE co-treatment significantly increased ($p<0.05$) testosterone in addition to restoring the LH and FSH levels near the levels of the control group. Additionally, GLE co-treatment increased sperm count, enhanced sperm viability, and improved sperm head morphology which agrees with the result of Uno *et al.* (2017). The improvement in the hormonal levels and sperm parameters observed in this study can be due to the content of GLE of vital minerals (Usunomena and Okolie, 2016) and to the antioxidant potentials of Graviola. Moreover, results showed a significant increase ($p<0.05$) in sperm DNA integrity accompanied by a significant decrease ($p<0.01$) in sperm DNA damage in the co-treated group with GLE compared with the CdCl₂ group. These results agree with George *et al.* (2015) who found that both aqueous and methanolic leaves extracts of *Graviola* have marked antioxidant properties along with DNA protective effects against H₂O₂-induced toxicity. The alterations in the expression of caspase-3, Bax, and Bcl-2 are a body mechanism to act against the degenerative effects caused by CdCl₂ in the testes. Interestingly, comparable to Cd intoxicated animals, GLE co-treated group showed significant down-regulate ($p<0.05$) in the expression levels of pro-apoptotic caspase-3 and Bax genes along with significant up-regulate ($p<0.05$) in the expression level of anti-apoptotic Bcl-2 gene (Fig. 5). These results agree with the results of Alsenosy *et al.* (2019) who found that *Graviola* treatment significantly reduced the expression of testicular genes Bax and inflammatory interleukin-1 β along with enhancing the testicular antioxidant status and the hormonal reproductive potential of the diabetic rats. The improvement in the genes expressions can be owed to the promotion of the antioxidant status and the reduction of lipid peroxidation as proved earlier in the results of the present work. Along with, the content of GLE with Annonacin acetogenin which recorded as being able to cause selectively cell death by apoptosis in the G1 phase of the cell cycle (Jacobo-Herrera *et al.*, 2019). Our result is in accordance with Zamudio-Cuevas *et al.* (2014) who concluded the cytoprotective capacity of *Graviola* against oxidative stress that prompted by ROS and its capacity to repair cellular damage.

Table 2. The effect of GLE on lipid peroxidation (MDA) and antioxidants levels in CdCl₂ treated rats.

Parameters	Experimental groups			
	Control	GLE (100mg/kg)	CdCl ₂ (5 mg/kg)	GLE (100mg/kg) + CdCl ₂ (5 mg/kg)
SOD enzyme (u/g)	7.8 \pm 0.08	8.4 \pm 0.10 ^c	5.6 \pm 0.45 ^{ab}	7.1 \pm 0.39 ^{bc}
CAT enzyme (u/g)	126.3 \pm 1.2	129 \pm 2.3 ^c	97.3 \pm 3.6 ^{ab}	111.4 \pm 1.4 ^{abc}
GSH level (mmol/g)	110.9 \pm 1.6	111.2 \pm 1.7 ^c	95.9 \pm 2.9 ^{ab}	107.3 \pm 2.0 ^c
MDA level (nmol/g)	20.05 \pm 0.6	19.9 \pm 0.4 ^c	44.08 \pm 1.19 ^{ab}	26.6 \pm 0.9 ^{abc}

All the values are presented as the mean \pm SEM (number of rats in each group = 8)

(a, b and c) indicates the significant change at $p<0.05$.

a = significance when compared with control, b = significance when compared with GLE group, and c= significance when compared with the CdCl₂ group.

Table 3. The effect of GLE and/or CdCl₂ on male sex hormones

Parameters	Experimental groups			
	Control	GLE (100mg/kg)	CdCl ₂ (5 mg/kg)	GLE (100mg/kg) + CdCl ₂ (5 mg/kg)
Testosterone level (ng/ml)	1.83 ± 0.15	1.9 ± 0.15 ^c	0.96 ± 0.09 ^{ab}	1.8 ± 0.08 ^c
LH (mIU/ml)	5.1 ± 0.14	4.8 ± 0.13 ^c	17.02 ± 0.58 ^{ab}	7.9 ± 0.37 ^c
FSH (mIU/ml)	1.09 ± 0.04	1.01 ± 0.02 ^c	3.6 ± 0.09 ^{ab}	1.8 ± 0.08 ^c

All the values are presented as the mean ±SEM (number of rats in each group=8)

(a, b and c) indicates the significant change at $p<0.05$.

a = significance when compared with control, b = significance when compared with GLE group, and c = significance when compared with CdCl₂ group.

Table 4. Sperm parameters and DNA integrity of rats supplemented with GLE and/or CdCl₂.

Parameters	Experimental groups			
	Control	GLE (100mg/kg)	CdCl ₂ (5 mg/kg)	GLE (100mg/kg) + CdCl ₂ (5 mg/kg)
Sperm count ($\times 10^6$ sperm /ml)	166.3 ± 1.67	163.8 ± 4.5 ^c	53.9 ± 2.9 ^{ab}	102.1 ± 4.2 ^c
Sperm motility (% motile sperm)	67.8 ± 1.8	68.4 ± 0.8 ^c	59.2 ± 1.9 ^{ab}	67.2 ± 1.3 ^c
Sperm viability (% viable sperm)	69.9 ± 1.7	70.1 ± 2.4 ^c	58.6 ± 2.7 ^{ab}	68.9 ± 0.99 ^c
Sperm morphology (% normal cell)	97.5 ± 1.2	97.2 ± 0.97 ^c	86.3 ± 2.9 ^{ab}	90.9 ± 1.5 ^{abc}
Sperm DNA integrity%	96.9 ± 1.6	97.6 ± 1.2 ^c	83.1 ± 4.4 ^{ab}	96.7 ± 1.8 ^c

All the values are presented as the mean ±SEM (number of rats in each group = 8)

(a, b and c) indicates the significant change at $p<0.05$.

a = significance when compared with control, b = significance when compared with GLE group, and c = significance when compared with the CdCl₂ group.

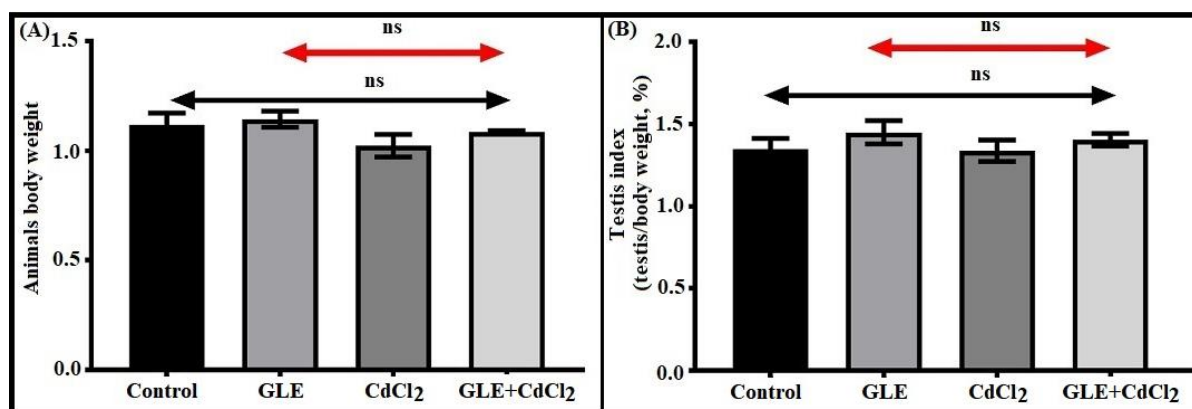


Fig. 1. (A) Changes in the rat body weight after cadmium and/or Graviola administration. (B) Changes in the rat testis index after cadmium and/or Graviola administration. All the values are presented as the mean ± SEM ($n = 8$), ns = statistically non-significance ($p>0.05$) between all treated groups.

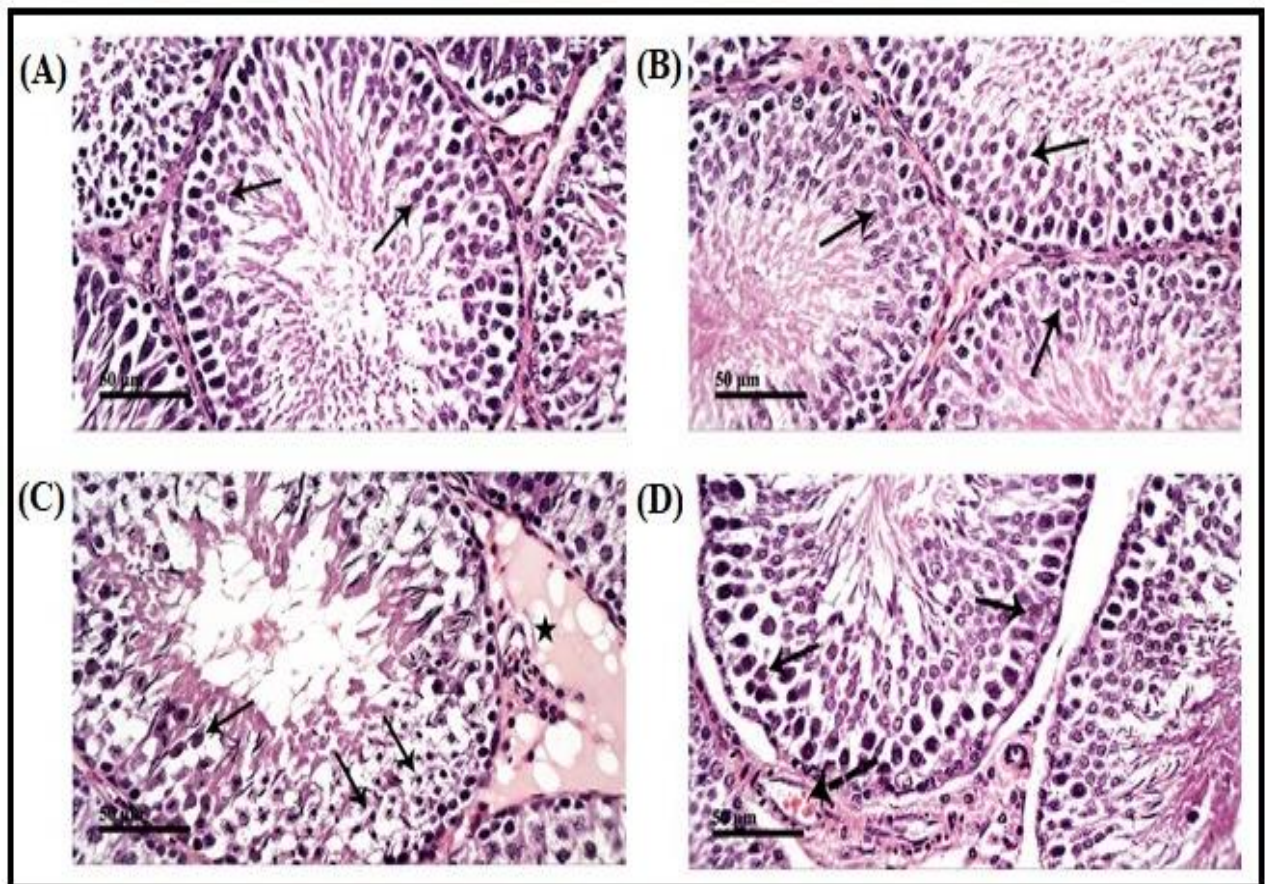


Fig. 2. Photomicrographs of rat testes showing normal tissue architecture in control (A) and GLE (B). Section from CdCl₂-exposed rats (C) reveals marked degenerative changes, vacuolation of germinal epithelium, and many figures of pyknotic nuclei (arrow) accompanied with interstitial oedema (star). Administration of GLE along with CdCl₂ (D) shows more organized almost intact germinal epithelium with milder records of degenerative changes and diminished interstitial oedema with mild congestion of intertubular blood vessels (dashed arrow).

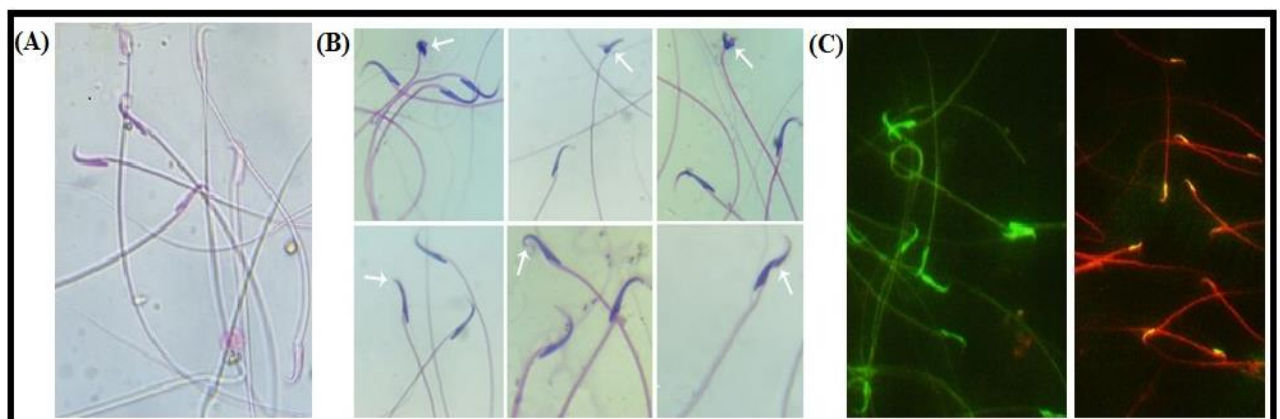


Fig. 3. Photomicrographs of sperm smears showing: (A) Sperm viability using Eosin-nigrosin stain, vital sperm (colourless), and dead sperm (red). (B) Sperm head abnormalities (arrows) using H&E stain (C) Sperm DNA integrity stained with AO, normal sperm (green), and abnormal sperm (yellow).

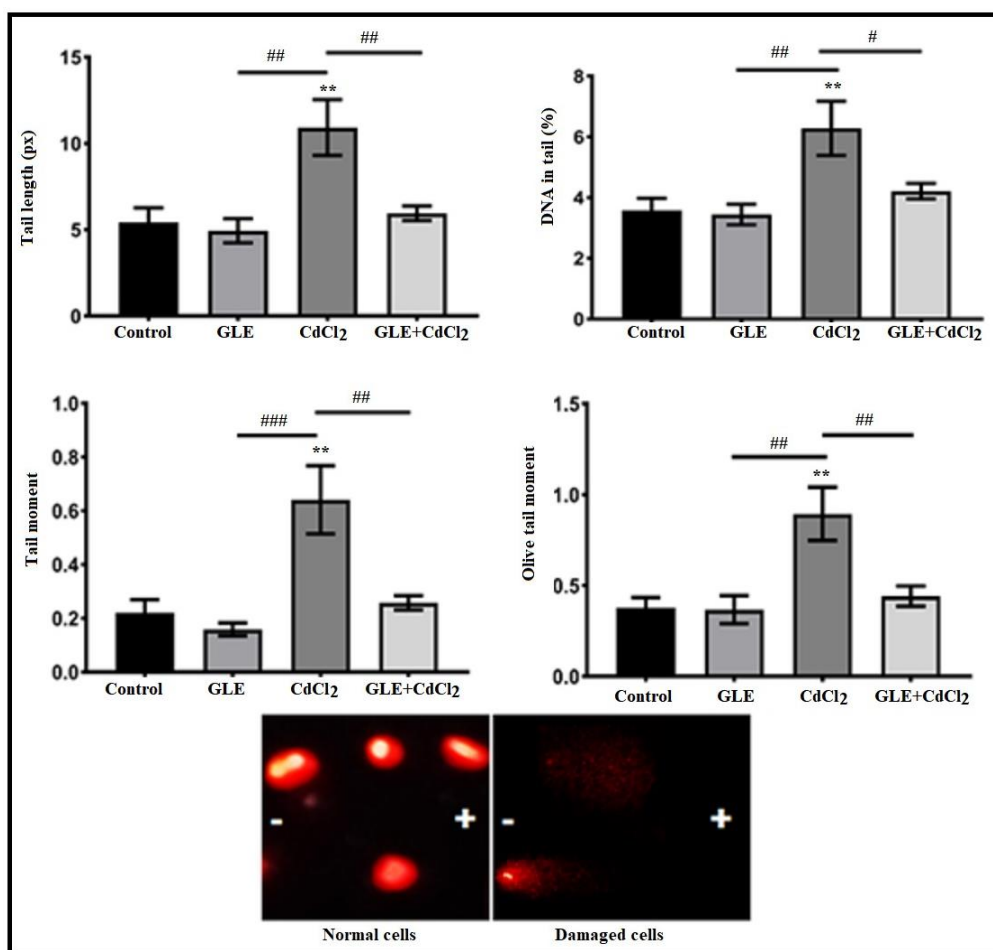


Fig. 4. The tail length, DNA% in the tail, tail moment and Olive tail moment recorded in the epididymal sperm of the control and all experimental treated groups. All the values are presented as the mean \pm SEM ($n = 8$). *Significantly different vs. control group ($p < 0.01$) and #Significantly different versus CdCl₂ group ($p < 0.05$, ## $p < 0.01$ and ### $p < 0.001$).

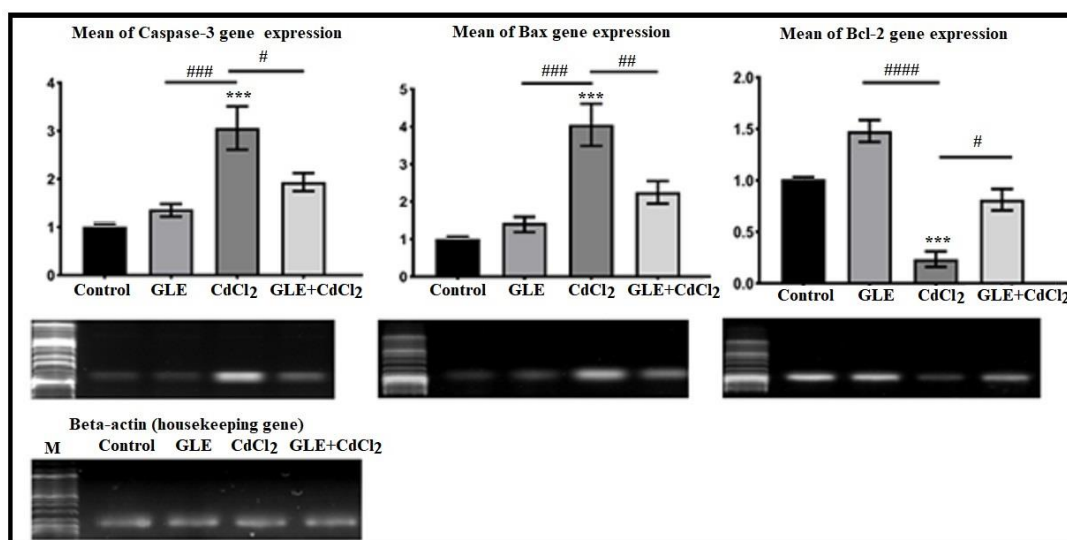


Fig. 5. Caspase-3, Bax, and Bcl-2 gene expression levels in the control, CdCl₂ and/or GLE-treated groups. All the values are presented as the mean \pm SEM ($n = 8$). *Significantly different vs. control group ($p < 0.001$) and #Significantly different versus CdCl₂ group ($p < 0.05$, ## $p < 0.01$, ### $p < 0.001$ and #### $p < 0.0001$).

CONCLUSION

Results of the present investigation concluded that Graviola (*Annona muricata*) leaves extract has a cytoprotective and therapeutic effect on testicular damage induced by cadmium and that pretreatment with GLE reverses the reproductive toxicity induced by CdCl₂ through improving both testicular antioxidant and anti-apoptotic mechanisms, thereby enhancing sperm quality and quantity and improving testicular lipid peroxidation status. However, further studies are required to study the exact molecular pathways responsible for its anti-apoptotic effects.

Authors' contributions

The authors participated equally in all parts of the research.

Conflict of interest

The authors declare that they have no conflict of interest.

REFERENCES

- Adefegha, S. A.; Oyeleye, S. I.; Obboh, G. (2015) Distribution of phenolic contents, antidiabetic potentials, antihypertensive properties, and antioxidative effects of soursop (*Annona muricata* L.) fruit parts in vitro. *Biochemistry Research International*, 2015:347673.
- Adewole, S. O. and Ojewole, J. A. (2008) Protective effects of *Annona muricata* Linn. (Annonaceae) leaf aqueous extract on serum lipid profiles and oxidative stress in hepatocytes of streptozotocin-treated diabetic rats. *African Journal of Traditional, Complementary and Alternative Medicines*, 6(1):30–41.
- Aebi, H. E. (1983) Catalase. In: Bergmeyer, HU (ed.). *Methods of enzymatic analysis*. Verlag Chemie, Weinheim, Germany, pp. 273–86.
- Agarwal, A. and Saleh, R. A. (2002) Role of oxidants in male infertility: rationale, significance, and treatment. *Urologic Clinics of North America*, 29(4):817–27.
- Agarwal, A.; Sharma, R. K.; Nallella, K. P.; Thomas, A. J. Jr.; Alvarez, J. G.; Sikka, S. C. (2006) Reactive oxygen species as an independent marker of male factor infertility. *Fertility and Sterility*, 86(4):878–85.
- Aitken, R. J. (1999) The amoroso lecture. The human spermatozoon—a cell in crisis? *Journal of reproduction and fertility*, 115(1):1–7.
- Alese, M. O.; Agbaje, M. A.; Alese, O. O. (2018) Cadmium induced damage in Wistar rats, ameliorative potentials of progesterone. *Journal of Trace Elements in Medicine and Biology*, 50:276–82.
- Alsenosy, A. w. A.; El-Far, A. H.; Sadek, K. M.; Ibrahim, S. A.; Atta, M. S.; Sayed-Ahmed, A. (2019) Graviola (*Annona muricata*) attenuates behavioural alterations and testicular oxidative stress induced by streptozotocin in diabetic rats. *PLoS One*, 14(9):e0222410.
- Awodele, O.; Ishola, I. O.; Ikumawoyi, V. O.; Akindele, A. J.; Akintonwa, A. (2013) Toxicological evaluation of the lyophilized fruit juice extract of *Annona muricata* Linn. (Annonaceae) in rodents. *Journal of Basic and Clinical Physiology and Pharmacology*, 18:1–11.
- Baltaci, A. K.; Mogulkoc, R.; Baltaci, S. B. (2019) Review: The role of zinc in the endocrine system. *Pakistan Journal of Pharmaceutical Sciences*, 32(1):231–239.
- Bertin, G. and Averbeck, D. (2006) Cadmium: cellular effects, modifications of biomolecules, modulation of DNA repair and genotoxic consequences (a review). *Biochimie*, 88(11):1549–59.

- Bu, T.; Mi, Y.; Zeng, W.; Zhang, C. (2011) Protective effect of quercetin on cadmium-induced oxidative toxicity on germ cells in male mice. *Anatomical record (Hoboken)*, 294(3):520–6.
- Casalino, E.; Calzaretto, G.; Sblano, C.; Landriscina, C. (2002) Molecular inhibitory mechanisms of antioxidant enzymes in rat liver and kidney by cadmium. *Toxicology*. 179(1–2):37–50.
- Coria-Téllez, A. V.; Montalvo-Gonzalez, E.; Yahia, E. M.; Obledo-Vázquez, E. N. (2018) *Annona muricata*: a comprehensive review on its traditional medicinal uses, phytochemicals, pharmacological activities, mechanisms of action and toxicity. *Arabian Journal of Chemistry*, 11(5):662–91.
- Cupertino, M. D. C.; Novaes, R. D.; Santos, E. C.; Bastos, D. S. S.; Marques Dos Santos, D. C.; do Carmo Queiroz Fialho, M.; Matta, S. L. P. D. (2017) Cadmium-induced testicular damage is associated with mineral imbalance, increased antioxidant enzymes activity and protein oxidation in rats. *Life Sciences*, 2017; 175:23–30.
- de Angelis, C.; Galdiero, M.; Pivonello, C.; Salzano, C.; Gianfrilli, D.; Piscitelli, P.; Lenzi, A.; Colao, A.; Pivonello, R. (2017) The environment and male reproduction: the effect of cadmium exposure on reproductive function and its implication in fertility. *Reproductive Toxicology*, 73:105–27.
- de Sousa, O. V.; Vieira, G. D.; de Jesus R G de Pinho, J.; Yamamoto, C. H.; Alves, M. S. (2010) Antinociceptive and anti-inflammatory activities of the ethanol extract of *Annona muricata* L. leaves in animal models. *International Journal of Molecular Sciences*, 11(5):2067-2078.
- Du Plessis, S. S.; Agarwal, A.; Halabi, J.; Tvrdá, E. (2015) Contemporary evidence on the physiological role of reactive oxygen species in human sperm function. *Journal of Assisted Reproduction and Genetics*, 32(4):509–20.
- Ellman, G. L. (1959) Tissue sulfhydryl groups. *Archives of Biochemistry and Biophysics*, 82(1):70–7.
- El-Sawi, M. R.; Abou-El-Naga, A. M.; Atta, M. S. and Shalaby, S. A. (2020) Effect of graviola leaves extract on nicotine induced reproductive damages in male albino rats. *IOSR Journal of Pharmacy and Biological Sciences*, 15(1):44–50.
- George, V. C.; Kumar, D. R.; Suresh, P. K.; Kumar, R. A. (2015) Antioxidant, DNA protective efficacy and HPLC analysis of *Annona muricata* (soursop) extracts. *Journal of Food Science and Technology*, 52(4):2328–35.
- Hengartner, M. O. (2000) The biochemistry of apoptosis. *Nature*. 407(6805):770–6.
- Henkel, R. R. (2011) Leukocytes and oxidative stress: dilemma for sperm function and male fertility. *Asian Journal of Andrology*, 13(1):43–52.
- Ikedobi, C. O.; Badisa, V. L.; Ayuk-Takem, L. T.; Latinwo, L. M.; West, J. (2004) Response of antioxidant enzymes and redox metabolites to cadmium-induced oxidative stress in CRL-1439 normal rat liver cells. *International Journal of Molecular Medicine*, 14(1):87–92.
- Jacobo-Herrera, N.; Pérez-Plasencia, C.; Castro-Torres, V. A.; Martínez-Vázquez, M.; González-Esquinca, A. R.; Zentella-Dehesa, A. (2019) Selective acetogenins and their potential as anticancer agents. *Frontiers in Pharmacology*, 10:783.
- Jomova, K. and Valko, M. (2011) Advances in metal-induced oxidative stress and human disease. *Toxicology*. 283(2–3):65–87.
- Kurutas, E. B. (2016) The importance of antioxidants which play the role in cellular response against oxidative/nitrosative stress: current state. *Nutrition Journal*, 15(1):71.
- Lech, T. and Sadlik, J. K. (2017) Cadmium concentration in human autopsy tissues. *Biological Trace Element Research*, 179(2):172–77.

- Lim, H.; Heo, M. Y.; Kim, H. P. (2019) Flavonoids: broad spectrum agents on chronic inflammation. *Biomolecules & Therapeutics* (Seoul), 27(3):241–53.
- Liu, Q.; Gu, J. H.; Yuan, Y.; Liu, X. Z.; Wang, Y. J.; Wang, H. D.; Liu, Z. P.; Wang, Z. Y.; Bian, J. C. (2016) Preventive effects of beta-cryptoxanthin against cadmium-induced oxidative stress in the rat testis. *Asian Journal of Andrology*, 18(6):920–24.
- Liu, Q.; Gu, J. H.; Yuan, Y.; Liu, X. Z.; Wang, Y. J.; Wang, H. D.; Liu, Z. P.; Wang, Z. Y.; Bian, J. C. (2013) Effect of cadmium on rat Leydig cell testosterone production and DNA integrity in vitro. *Biomedical and Environmental Sciences*, 26(9):769–73.
- Livak, K. J. and Schmittgen, T. D. (2001) Analysis of relative gene expression data using real-time quantitative PCR and the 2(-Delta Delta C(T)) Method. *Methods*, 25(4):402–8.
- Marettova, E.; Mareta, M.; Legath, J. (2015) Toxic effects of cadmium on testis of birds and mammals: a review. *Animal Reproduction Science*, 155:1–10.
- Mishra, S.; Ahmad, S.; Kumar, N.; Sharma, B. K. (2013) *Annona muricata* (the cancer killer): a review. *Global Pharmaceutical Research*, 2:1613–1618.
- Moghadamtousi, S. Z.; Rouhollahi, E.; Hajrezaie, M.; Karimian, H.; Abdulla, M. A.; Kadir, H. A. (2015) *Annona muricata* leaves accelerate wound healing in rats via involvement of Hsp70 and antioxidant defence. *International Journal of Surgery*, 18:110–117.
- Monsefi, M.; Alaei, S.; Moradshahi, A.; Rohani, L. (2010) Cadmium-induced infertility in male mice. *Environmental Toxicology*, 25(1):94–102.
- Mouro, V. G. S.; Siman, V. A.; da Silva, J.; Dias, F. C. R.; Damasceno, E. M.; Cupertino, M. D. C.; de Melo, F. C. S. A.; da Matta, S. L. P. (2019) Cadmium-induced testicular toxicity in mice: subacute and subchronic route-dependent effects. *Biol Trace Elem Res*. <https://doi.org/10.1007/s12011-019-01731-5>.
- Muthu, S. and Durairaj, B. (2015) Evaluation of antioxidant and free radical scavenging activity of *Annona muricata*. *European Journal of Experimental Biology*, 5(3):39–45.
- Nair, A. R.; DeGheselle, O.; Smeets, K.; Emmy Van Kerkhove, E. V.; Cuypers, A. (2013) Cadmium-induced pathologies: where is the oxidative balance lost (or not)? *International Journal of Molecular Sciences*, 14(3):6116–43.
- Nna, V. U.; Ujah, G. A.; Mohamed, M.; Etim, K. B.; Igba, B. O.; Augustine, E. R.; Osim, E. E. (2017) Cadmium chloride-induced testicular toxicity in male wistar rats; prophylactic effect of quercetin, and assessment of testicular recovery following cadmium chloride withdrawal. *Biomedicine & Pharmacotherapy*, 94:109–23.
- Olakunle, S.; Onyechi, O.; James, O. (2014) Toxicity, anti-lipid peroxidation, invitro and invivo evaluation of antioxidant activity of *Annona muricata* ethanol stem bark extract. *American Journal of Life Sciences*, 2(5):271–77.
- Patra, R. C.; Rautray, A. K.; Swarup, D. (2011) Oxidative stress in lead and cadmium toxicity and its amelioration. *Veterinary Medicine International*. 2011:457327.
- Pederson, M. A.; Scott, C. S.; William, A. B. (1990) Evaluation of lipid peroxidation in inflammatory patients. *Annals of the New York Academy of Sciences*, 559, 45.
- Pomper, K. W.; Lowe, J. D.; Crabtree, S. B.; Keller, W. (2009) Identification of annonaceous acetogenins in the ripe fruit of the North American pawpaw (*Asimina triloba*). *Journal of Agricultural and Food Chemistry*, 57(18):8339–43.
- Qazi, A. K.; Siddiqui, J. A.; Jahan, R.; Chaudhary, S.; Walker, L. A.; Sayed, Z.; Jones, D. T.; Batra, S. K.; Macha, M. A. (2018) Emerging therapeutic potential of graviola and its constituents in cancers. *Carcinogenesis*. 39(4):522–533.
- Quílez, A. M.; Fernández-Arche, M. A.; García-Giménez, M. D.; De la Puerta, R. (2018) Potential therapeutic applications of the genus *Annona*: local and traditional uses and pharmacology. *Journal of Ethnopharmacology*, 225:244–70.

- Rezvanfar, M. A.; Sadrkhanlou, R. A.; Ahmadi, A.; Shojaei-Sadee, H.; Rezvanfar, M. A.; Mohammadirad, A.; Salehnia, A.; Abdollahi, M. (2008) Protection of cyclophosphamide-induced toxicity in reproductive tract histology, sperm characteristics, and DNA damage by an herbal source; evidence for role of free-radical toxic stress. *Human and Experimental Toxicology*, 27:901–10.
- Richter, P.; Faroon, O.; Pappas, R. S. (2017) Cadmium and cadmium/zinc ratios and tobacco-related morbidities. *International Journal of Environmental Research and Public Health*, 14:1154(10).
- Saha, R.; Roychoudhury, S.; Kar, K.; Varghese, A. C.; Nandi, P.; Sharma, G. D.; Formicki, G.; Slama, P.; Kolesarova, A. (2019) Coenzyme Q10 ameliorates cadmium induced reproductive toxicity in male rats. *Physiological Research*, 68(1):141–145.
- Satarug, S.; Garrett, S. H.; Sens, M. A.; Sens, D. A. (2010) Cadmium, environmental exposure, and health outcomes. *Environmental Health Perspectives*, 118(2):182–90.
- Simon, L. and Carrell, D. T. (2013) Sperm DNA damage measured by comet assay. In: Carrell D, Aston K (eds.). *Spermatogenesis. Methods in molecular biology (methods and protocols)*, vol 927, Humana Press, Totowa, NJ.
- Siu, E. R.; Mruk, D. D.; Porto, C. S.; Cheng, C. Y. (2009) Cadmium-induced testicular injury. *Toxicology and Applied Pharmacology*, 238(3):240–9.
- Sun, Y.; Oberley, L.W.; Li, Y. (1988) A simple method for clinical assay of superoxide dismutase. *Clinical Chemistry*, 34(3):497–500.
- Tejada, R. I.; Mitchell, J. C.; Norman, A.; Marik, J. J.; Friedman, S. (1984) A test for the practical evaluation of male fertility by acridine orange (AO) fluorescence. *Fertility and Sterility*, 42(1):87–91.
- Turner, T. T. and Lysiak, J. J. (2008) Oxidative stress: a common factor in testicular dysfunction. *Journal of Andrology*, 29(5):488–98.
- Uno, U. U.; Ogbe, H. O.; Okolo, C. M. (2017) Effect of Soursop (*Annona muricata*.) Leaf extract on sperm toxicity induced by caffeine in Albino Rats. *Pharmaceutical Chemistry Journal*, 4(1):82–7.
- Usunomena, U. and Okolie, N. (2016) Phytochemical analysis and mineral composition of *Annona muricata* leaves. *International Journal of Development Research*, 1(1):7–10.
- Valko, M.; Morris, H.; Cronin, M. T. (2005) Metals, toxicity and oxidative stress. *Current Medicinal Chemistry*, 12(10):1161–208.
- Vijayameena, C.; Subhashini, G.; Loganayagi, M.; Ramesh, B. (2013) phytochemical screening and assessment of antibacterial activity for the bioactive compounds in *Annona muricata*. *International Journal of Current Microbiology and Applied Sciences*, 2(1):1–8.
- Wang, L.; Xu, T.; Lei, W. W.; Liu, D. M.; Li, Y. J.; Xuan, R. J.; Ma, J. J. (2011) Cadmium-induced oxidative stress and apoptotic changes in the testis of freshwater crab, *Sinopotamon henanense*. *PLoS One*, 6(11):e27853.
- Yang, C.; Gundala, S. R.; Mukkavilli, R.; Vangala, S.; Reid, M. D.; Aneja, R. (2015) Synergistic interactions among flavonoids and acetogenins in Graviola (*Annona muricata*) leaves confer protection against prostate cancer. *Carcinogenesis*, 36(6):656–65.
- Yari, A.; Sarveazad, A.; Asadi, E.; Raouf, Sarshoori, J.; Babahajian, A.; Amini, N.; Amidi, F.; Bahadoran, H.; Joghataei, M. T.; Asadi, M. H.; Shams, A. (2016) Efficacy of *Crocus sativus* L. on reduction of cadmium-induced toxicity on spermatogenesis in adult rats. *Andrologia*, 48(10):1244–52.
- Zamudio-Cuevas, Y.; Díaz-Sobac, R.; Vázquez-Luna, A.; Landa-Solís, C.; Cruz-Ramos, M.; Santamaría-Olmedo, M.; Martínez-Flores, K.; Fuentes-Gómez, A. J.; López-Reyes,

A. (2014) The antioxidant activity of soursop decreases the expression of a member of the NADPH oxidase family. *Food and the functions*, 5(2):303–9.

ARABIC SUMMARY

التأثير الوقائي لمستخلص أوراق الجرافيو لا (أننونا موريكاتا) ضد سمية الخصية التي يسببها الكادميوم في ذكور الجرذان البيضاء

داليا دمرdash عبد المنعم وشيرين حسن بدوى الوكيل

قسم علم الحيوان - كلية البنات للعلوم والآداب والتربية - جامعة عين شمس - شارع أسماء فهمى - هليوبوليس- القاهرة - مصر

يُعتبر نبات القشدة (أننونا موريكاتا) الذي ينتمي إلى عائلة القشديات من النباتات الصالحة للأكل والتي لها تاريخ طويل في الطب التقليدي وذلك بسبب مداها العلاجي الواسع للعديد من الأمراض. فقد تم تخطيط هذه الدراسة لتقييم قدرة مستخلص أوراق القشدة على حماية ذكور الجرذان البيضاء من حدوث تلف الخصية الناجم عن التعرض لمادة الكادميوم. حيث تم إجراء الدراسة على 32 من ذكور الجرذان البالغة ، والتي تم توزيعها عشوائياً إلى أربع مجموعات ، ثمانية حيوانات لكل مجموعة. المجموعة (أ) مجموعة ضابطه، المجموعة (ب) وقد تلقت 100 مجم/كجم من مستخلص أوراق القشدة ، المجموعة (ج) وقد تلقت 5مجم/كجم من كلوريد الكادميوم ، بينما تلقت المجموعة (د) 100مجم/كجم من مستخلص أوراق نبات القشدة بالإضافة إلى 5 مجم/كجم كلوريد الكادميوم. وقد تمت كل المعالجات بواسطة التجريع من خلال الفم يوميا لمدة ثمانية أسابيع. ثم تم تجميع كلا من الدم ، الخصيتين ، و البربخ لإجراء الاستقصاءات البيوكيميائية و النسيجية بالإضافة إلى تحليل الحيوانات المنوية ، و مقايصة المذنب للحمض النووي الريبوزي منقوص الأكسجين (الدنا) بالحيوانات المنوية ، و تقييم مؤشرات الموت المبرمج للخلايا. وقد أظهرت النتائج أن مستخلص أوراق نبات القشدة قد عكس بشكل ذو دلالة معنوية ($p<0.05$) الاجهاد التأكسدي للخصية الناجم عن التعرض لكلوريد الكادميوم، كما حافظ على مستويات الهرمونات الجنسية الذكرية ، وعمل على استعادة التركيب النسيجي للخصية من خلال زيادة معدل مضادات الأكسدة في الخصية. كما أدى العلاج المشترك لمستخلص أوراق نبات القشدة إلى أحداث زيادة معنوية ($p<0.05$) في عدد الحيوانات المنوية ، و حركتها ، و حيوتها ، وسلامة الحمض النووي، ذلك بالإضافة إلى التقليل بشكل كبير من تكسر الحمض النووي و تشوه الشكل المورفولوجي لرأس الحيوانات المنوية وذلك بالمقارنة مع المجموعة (ج) المعالجه بكلوريد الكادميوم فقط. بالإضافة إلى ذلك قامت القشدة بحماية الخلايا الجرثومية من حدوث موت الخلايا المبرمج الناجم عن التعرض للكادميوم. وختاماً قد أكدت نتائج الدراسة الحالية أن خلاصة أوراق نبات القشدة له إمكانية قوية كمضاد للأكسدة وقدرة على الحماية الخلوية من الآثار الضارة لكلوريد الكادميوم على أنسجة الخصية من خلال الحد من الاجهاد التأكسدي للخلايا الناجم عن توليد أنواع الأكسجين التفاعلية.